

## CARDIOTHORACIC SURGERY

## UPDATE

## Inside This Edition

- 2 Robotic First Rib Resection for Thoracic Outlet Syndrome
- 4 Endovascular Repair of the Ascending Aorta
- 6 Lung Transplantation in the Midst of the COVID Pandemic
- 8 Primary Cardiac Tumors: Surgical Treatment Improves Survival
- 10 Department News
- 12 Clinical Trials
- 14 Welcoming New Faculty

## CME Credit

**Disclosures:** Dr. Sultan reports the following relevant interest: Investigator Initiated Research Grant from Articure and Research Support from Medtronic. Drs. Sarkaria, Baker, Levy, Serna-Gallegos, Harano, Chan, Sanchez, and Bianco report no relationships with proprietary entities producing health care goods or services.

**Instructions:** To take the CME evaluation and receive credit, please visit [UPMCPhysicianResources.com/ThoracicSurgery](https://UPMCPhysicianResources.com/ThoracicSurgery), and click on UPMC Cardiothoracic Surgery Update Summer 2021.

**Accreditation Statement:** In support of improving patient care, the University of Pittsburgh is jointly accredited by the Accreditation Council for Continuing Medical Education (ACCME), the Accreditation Council for Pharmacy Education (ACPE), and the American Nurses Credentialing Center (ANCC), to provide continuing education for the health care team.

The University of Pittsburgh designates enduring material activity for a maximum of 0.5 AMA PRA Category 1 Credit™. Physicians should claim only the credit commensurate with the extent of their participation in the activity.

Other health care professionals will receive a certificate of attendance confirming the number of contact hours commensurate with the extent of participation in this activity.

## Dear Colleagues,

As founding chairman of the UPMC Department of Cardiothoracic Surgery, I am pleased to present this issue of *Cardiothoracic Surgery Update*.

Since its inception, the UPMC Department of Cardiothoracic Surgery has established treatment advancements and championed outstanding clinical outcomes in the fields of thoracic and foregut surgery, adult cardiac surgery, pediatric cardiothoracic surgery, and cardiothoracic transplant. Our comprehensive range of diagnostic and treatment modalities, along with the continued development of these innovative techniques, has allowed us to deliver the highest quality of care for a full range of cardiothoracic diseases and disorders – including complex cases turned down at other centers.

In this issue, we celebrate the successes of our dedicated faculty and provide updates on upcoming events, clinical trials, and research initiatives. Starting with the expertise of Inderpal S. Sarkaria, MD, MBA, FACS, director of Thoracic Robotic Surgery and Nicholas Baker, MD, assistant professor of Cardiothoracic Surgery, who have leveraged the power of robotic surgery to offer robotic rib resection for the treatment of thoracic outlet syndrome (TOS)— changing the paradigm for care and providing an excellent application for this technology. Additionally, we celebrate the accomplishments of experts from the Division of Adult Cardiac Surgery, part of the Department of Cardiothoracic Surgery at UPMC, who performed endovascular repair of the ascending aorta for the first time, which previously had not been considered amenable to endovascular repair due to its physiology and anatomy. Also in this issue, we share news of a collaborative approach between our team and experts in the Division of Cardiology to determine the best treatment approach for patients with primary cardiac tumors. Valentino Bianco, DO, MPH, and Ibrahim Sultan, MD, FACS, present their findings from a study that analyzed how surgical resection and other treatments affected patient survival, and became a guide to better understanding the typical profile of patients with a primary cardiac tumor.

Lastly, we address the global COVID-19 pandemic. As COVID-19 cases began to rise in the United States, experts from the Division of Lung Transplant and Lung Failure quickly developed a plan to offer safe and essential care to patients with lung disease. By limiting lung transplantation to only the sickest patients and implementing additional testing policies for donors, we have been able to limit possible spread of COVID-19 among patients, preserve medical resources, and continue to provide life-saving lung transplants to patients at UPMC.

I am extremely proud of our Department and our continued plans for clinical and academic growth. I look forward to keeping you up to date on future progress and developments.

For more information about our program, please visit [UPMCPhysicianResources.com/ThoracicSurgery](https://UPMCPhysicianResources.com/ThoracicSurgery).



**James D. Luketich, MD, FACS**

Henry T. Bahnson Professor and Chairman,  
UPMC Department of Cardiothoracic Surgery  
Chief, Division of Thoracic and Foregut Surgery  
Director, UPMC Esophageal and Lung Surgery Institute  
Director, Thoracic Surgical Oncology

# Robotic First Rib Resection for Thoracic Outlet Syndrome at UPMC

by Nicholas Baker, MD; Ryan M. Levy, MD; and Inderpal Sarkaria, MD, MBA, FACS

Robotic surgery is an advanced form of minimally invasive surgery that offers several potential advantages over conventional approaches. The surgical robot gives exquisite control of highly maneuverable tools and imparts high-resolution visualization. The well-characterized benefits of minimally invasive surgery, such as faster recovery times and fewer postoperative complications, seem to carry over to minimally invasive robotic surgeries.

In the Division of Thoracic Surgery, part of the UPMC Department of Cardiothoracic Surgery, we extensively leverage the power of robotic thoracic surgery, performing robotic lobectomy and segmentectomy, robotic thymectomy for the treatment of thymoma and myasthenia gravis, robotic paraesophageal hernia repair, and robotic minimally invasive esophagectomy.<sup>1-4</sup> We pioneered near-infrared fluorescence imaging protocols to visualize tumors and vasculature in vivo using the robotic cameras.<sup>5,6</sup> In 2020, we expanded our armamentarium for care by incorporating robotic first rib resection for the treatment of thoracic outlet syndrome (TOS).

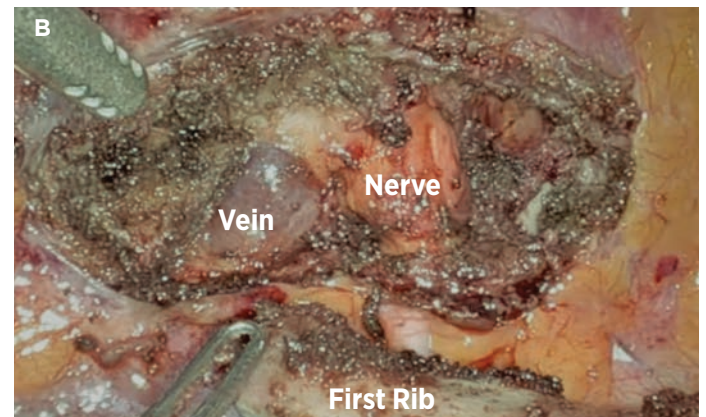
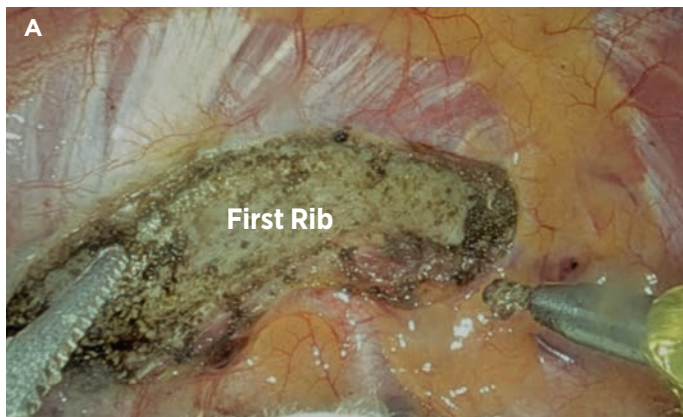TOS is characterized by upper extremity pain and paresthesia due to musculoskeletal compression of nerves and blood vessels passing through the thoracic outlet. There are three types of TOS: arterial, venous, and neurogenic. The neurogenic type is the most common

presentation and comprises more than 90% of cases.<sup>7</sup> The brachial nerve plexus is compressed by the first rib and scalene muscles. Patients typically experience numbness and tingling in the affected arm, though progressive muscle atrophy can occur in rare cases. Although less common, vascular variants, such as Paget-Schroetter syndrome, can present with symptoms of chronic ischemia and venous thrombosis.

TOS is often initially diagnosed functionally using non-invasive assessments, and treating patients with TOS requires a multidisciplinary approach with the involvement of thoracic surgeons, as well as physicians from physical therapy, pain management, neurology, neurosurgery, orthopaedic surgery, and vascular surgery as needed to tailor the assessment and care of any given patient. Nonoperative options for TOS should be exhausted before operative management is considered. We routinely collaborate with physicians in the Department of Physical Medicine and Rehabilitation, who are essential to our team. Physical therapy, modification of daily activities, and pain management are typically employed for symptom relief. If appropriate physical therapy from a knowledgeable therapist and other measures do not improve TOS symptoms, an anterior scalene diagnostic nerve block is indicated. Responsiveness to the anesthetic is an indicator of whether the patient may respond to first rib resection.<sup>7</sup> In one study, 94% of patients with temporary symptom

relief from an anterior scalene nerve block had durable symptom relief six months after surgery, but only 50% of the patients who underwent surgery but were non-responsive to the nerve block experienced alleviation of their symptoms after surgery.<sup>8</sup> If the nerve block relieves the patient's TOS symptoms, a physiologic assessment and CT scan are indicated. It is important to know if a cervical rib is present, as this may alter the surgical approach. We sometimes obtain electromyography (EMG) to look for nerve conduction delays that may indicate an alternative diagnosis. Referral to other surgical specialists, such as neurosurgery, upper extremity orthopaedics, or vascular surgery, may be needed to rule out other diagnoses that could be causing arm pain. After determining that the patient is a good candidate for first rib resection surgery, we choose our approach for treatment.

First rib resection for TOS has traditionally been performed using open techniques with axillary (armpit) or supraclavicular (above the collar bone) surgical approaches. Video-assisted transthoracic thoracoscopic approaches have not been frequently used due to difficulty reaching the apex of the chest using traditional thoracoscopic tools. Robot-assisted thoracoscopic surgery has changed this paradigm and made the procedure easier to complete in a minimally invasive fashion by providing superior direct exposure of the first rib and thoracic outlet from within the chest, and highly sophisticated tools with which to perform.



**Figure 1.** Robotic first rib resection for TOS. **A.** Transthoracic exposure of the first rib after division of the mediastinal pleura. **B.** View of the thoracic outlet after rib resection but prior to removal of the rib fragment. The subclavian artery and vein, brachial plexus, and scalene muscles are clearly visualized.

The enhanced optics and highly articulated tools provided by the surgical robot are ideal for the procedure. Using the robot for a transthoracic thoracoscopic approach provides very clear exposure of the first rib, phrenic nerve, superior vena cava, and major vessels. The intercostal muscles and mediastinal pleura are dissected from the first rib (Figure 1A), and the costal cartilage connecting the rib to the sternum is divided. A bone cutter or bone drill is employed to divide the first rib under excellent direct vision with a high margin of safety. After the rib is divided, the surgeon divides the scalene muscles, performs lysis of fibrotic adhesions on the brachial plexus and subclavian vein as needed, and removes the rib (Figure 1B).<sup>9</sup> Unlike most open approaches, nearly the entire rib is removed from the costal cartilage junction to the transverse process of the spine to give the best possible chance of release of the pathologic constriction of the thoracic outlet. Patients are asked to complete the Disabilities of the Arm, Shoulder, and Hand (DASH) questionnaire preoperatively and postoperatively to objectively measure the success of the procedure.

Robotic first rib resection seems to benefit both the surgeon and the patient. Open resection via either a transaxillary or supraclavicular approach gives limited exposure of the first rib and requires retraction of the brachial plexus. With a minimally invasive transthoracic approach, the entire rib can be easily visualized and the brachial plexus does not have to be retracted for access. Therefore, robotic resection may reduce neurovascular complications. In the largest series of robotic first rib resections published to date, 83 robotic first rib resections were performed in patients with Paget-Schroetter syndrome, a type of venous TOS. All the surgeries were successfully completed without conversion to an open procedure, surgical complications, neurovascular injuries, or mortality.<sup>10</sup> Similarly, in a published series of eight robotic first rib resections for neurogenic TOS with review

of an additional 14 cases in the literature, there were no surgical complications or conversions to open surgery. Most patients were discharged on the first day postoperatively, and experienced complete and continued resolution of symptoms during follow up.<sup>11</sup> Our early results at UPMC echo these findings.

We are excited to offer robotic first rib resection to our patients at UPMC. It is an elegant and safe method to conduct surgery for TOS that previously was difficult due to the anatomy of the region with the increased potential for neurovascular complications due to the manipulations required for access during open surgery. Because robotic surgery entails telemanipulation of advanced instruments that the surgeon controls completely, each surgeon's experience and judgement are critical in conducting the procedure safely. The Division of Thoracic Surgery at UPMC is internationally recognized for its innovation and leadership in minimally invasive surgery, including its expertise and outcomes in robotic-assisted operations ranging from the most common to the most advanced and complex procedures, which are often reserved for open only approaches at most institutions. The addition of robotic-assisted surgery for the treatment of TOS is a natural extension of that commitment to less-invasive, high-quality surgery for our patients with diseases of the chest and foregut.

In the UPMC Department of Cardiothoracic Surgery, we continue to spearhead advancements and education in robotic thoracic surgery. Robotic first rib resection for TOS is an excellent application of this technology given the tight spaces and difficult angles of dissection mandated by the patient's anatomy. The multidisciplinary program that we have developed ensures that patients are appropriately diagnosed with TOS and directed to surgery if it is likely to alleviate their symptoms and improve their general well-being after nonoperative approaches have been attempted.

## References

- Sarkaria IS, Gorrepati ML, Mehendale S, Oh DS. Lobectomy in octogenarians: real world outcomes for robotic-assisted, video-assisted thoracoscopic, and open approaches. *J Thorac Dis.* 2019;11(6):2420-2430.
- Sarkaria IS, Latif MJ, Bianco VJ, et al. Early operative outcomes and learning curve of robotic assisted giant paraesophageal hernia repair. *Int J Med Robot.* 2017;13(1).
- Sarkaria IS, Rizk NP, Goldman DA, et al. Early Quality of Life Outcomes After Robotic-Assisted Minimally Invasive and Open Esophagectomy. *Ann Thorac Surg.* 2019;108(3):920-928.
- Baker N, Levy RM, Chan E, Sarkaria IS. Model for Implementing a Robotic Surgical Platform in an Established Minimally Invasive Thoracic University Affiliated Community Practice. Poster presented at Eastern Cardiothoracic Surgical Society 57th Annual Meeting Oct. 18, 2019; Naples, FL.
- Okusanya OT, Hess NR, Luketich JD, Sarkaria IS. Infrared intraoperative fluorescence imaging using indocyanine green in thoracic surgery. *Eur J Cardiothorac Surg.* 2018; 53(3):512-518.
- Sarkaria IS, Bains MS, Finley DJ, et al. Intraoperative near-infrared fluorescence imaging as an adjunct to robotic-assisted minimally invasive esophagectomy. *Innovations (Phila).* 2014;9(5):391-393.
- Burt BM. Thoracic outlet syndrome for thoracic surgeons. *J Thorac Cardiovasc Surg.* 2018;156(3):1318-1323 e1311.
- Jordan SE, Machleder HI. Diagnosis of thoracic outlet syndrome using electrophysiologically guided anterior scalene blocks. *Ann Vasc Surg.* 1998;12(3):260-264.
- Burt BM, Palivela N, Goodman MB. Transthoracic Robotic First Rib Resection: Technique Crystallized. *Ann Thorac Surg.* 2020;110(1):e71-e73.
- Gharagozloo F, Meyer M, Tempesta B, Gruessner S. Robotic transthoracic first-rib resection for Paget-Schroetter syndrome. *Eur J Cardiothorac Surg.* 2019;55(3):434-439.
- Pupovac SS, Lee PC, Zeltsman D, Jurado J, Hyman K, Singh V. Robotic-Assisted First Rib Resection: Our Experience and Review of the Literature. *Semin Thorac Cardiovasc Surg.* 2020.



### Nicholas Baker, MD

Assistant Professor of Cardiothoracic Surgery

### Ryan M. Levy, MD

Vice Chairman, Community Relations and Thoracic Expansion Chief, Thoracic Surgery, UPMC Passavant

### Inderpal S. Sarkaria, MD, MBA, FACS

Vice Chairman, Clinical Affairs  
Co-Director, UPMC Esophageal and Lung Surgery Institute  
Director, Thoracic Robotic Surgery  
Director, Thoracic Surgery Quality and Outcomes

# Endovascular Repair of the Ascending Aorta

by Derek R. Serna-Gallegos, MD; and Ibrahim Sultan, MD, FACS

Endovascular repair of the aorta with placement of stent grafts has become an established treatment for aortic dissections, aneurysms, and intramural hematomas in the descending thoracic and abdominal aorta. In contrast, the ascending aorta has previously not been considered amenable to endovascular repair due to its physiology and anatomy. The ascending aorta is larger and more dynamic than more distal segments of the aorta and undergoes vast conformational changes with each heartbeat. In contrast, the stent-grafts used for endovascular repair are relatively static and are at risk for being dislodged due to the very dynamic environment of the ascending aorta. Additionally, there are several major arteries that branch off the ascending aorta and occlusion of these will lead to ischemic complications affecting the brain or upper extremities. For these reasons, endovascular repair has not become the standard of care for dissections and aneurysms of the ascending aorta.

In the Division of Adult Cardiac Surgery, part of the Department of Cardiothoracic Surgery at UPMC, we routinely perform endovascular repair on the descending thoracic and abdominal aorta.<sup>1,2</sup> During the Summer of 2020, we performed endovascular repair of the ascending aorta for the first time.

Dissection of the ascending aorta is a very serious condition and is often fatal. When aortic dissections are detected with sufficient time to intervene, they are most commonly treated with open surgery to resect and replace the defect with a tube graft. If the patient is too frail or otherwise not a good candidate for surgery, the dissection is treated medically by ameliorating symptoms, such as chest pain, and controlling blood pressure to reduce the risk of rupture. The patient is closely monitored because the aortic dissection may rupture or cause malperfusion, which can lead to a cerebrovascular accident (CVA) or limb ischemia if the dissection flap occludes

branches of the aorta. Open surgery can be performed safely in many patients. Endovascular repair should only be considered when the patient is a poor candidate for surgery due to comorbidities or when the patient has a specific type of ascending aortic dissection that is highly amenable to thoracic endovascular aortic repair (TEVAR).

Due to the considerable challenges present in the ascending aorta, the pool of patients for whom TEVAR is considered appropriate is small. The lesion must be anatomically amenable to TEVAR. There must be proximal and distal landing zones of at least 1 cm that do not compromise the coronary ostia or the arch vessels, and the ascending aorta must accommodate a stent-graft within the treatment sizing range.<sup>3</sup> Additionally, cardiac revascularization procedures can pose an important limitation for TEVAR in the ascending aorta because previous coronary bypass grafts may be occluded with stent-graft coverage in the ascending aorta, and the presence of a stent may prevent future revascularization.<sup>4</sup> To date, TEVAR in the ascending aorta has only been performed in high-volume centers with experienced specialized aortic teams, like UPMC.

We treated a 67-year-old woman with multiple comorbidities, including chronic obstructive pulmonary disease (COPD) and chronic renal failure. She was initially admitted to an outside hospital because of exacerbation of her COPD, which caused pneumonia and respiratory failure necessitating a tracheostomy. While hospitalized, she had a CVA. Imaging to evaluate the CVA revealed a type A aortic dissection — a tear in the ascending aorta. This discovery prompted the patient's physician to contact the UPMC Department of Cardiothoracic Surgery, and she was transferred to UPMC Shadyside. We encourage referral of any patient with an aortic dissection to the UPMC Center for Thoracic Aortic Disease for evaluation. This allows us to comprehensively examine

each patient and assess our ability to treat them with appropriate surgical strategies or medical care. Further evaluation of this patient's imaging studies and an echocardiogram allowed us to classify her dissection as a DeBakey Type II aortic dissection, a dissection confined to the ascending aorta. In other words, the patient had a very contained, discrete defect. Additionally, the patient was relatively young, but her comorbidities made her a poor surgical candidate. Repair was urgent, but emergency repair was not warranted given the likely subacute nature of the incidentally discovered dissection. This patient clearly met criteria that others have used to define appropriate patients for endovascular repair of the ascending aorta.

A systematic review of reports of TEVAR of the ascending aorta published between 1995 to 2017 found 46 publications detailing primary endovascular repair of the ascending aorta using stent grafts in a total of 118 patients.<sup>5</sup> Most of the publications were case reports or series with 10 or fewer patients, although one series reported outcomes for 15 patients, and the largest series contained 21 patients. Half of the 118 patients (50%) had a type A aortic dissection, the same diagnosis as our patient. Patients were also treated for aortic pseudoaneurysm (30%), aortic aneurysm (5%), penetrating ulcer as a result of atherosclerosis (4%), and aortic rupture (2%). The most common approaches were transfemoral and transapical. The delivery system for the stent used for repair dictated the approach in some patients. Endoleaks, a complication unique to endovascular stenting that occurs when blood leaks around the outside of the stent, occurred in 18% of the patients. This is significantly higher than the incidence of endoleak reported for TEVAR of the thoracic descending aorta (<10%) and is likely a limitation of the current technology. Other complications included postoperative myocardial infarction (3%), cerebrovascular complications (3%), and stent migration

(2%). Respiratory complications have also been reported after TEVAR in the ascending aorta. Of the 118 endovascular procedures, four (3.4%) required conversion to open surgery, and 11 required surgical re-intervention (9%). In the largest series of TEVAR of the ascending aorta published to date, 9% of procedures required conversion to open surgery, and 32% of survivors (6 of 19) required surgical re-intervention.<sup>6</sup> It is worth noting, however, that two of these re-interventions were planned prior to the initial TEVAR. In the systematic review, all-cause mortality after TEVAR of the ascending aorta was 15%, and aorta-related mortality was 5%. Two-thirds of the patients (67%) remained free of aorta-related complications during follow up, and 60.2% did not experience any complications during follow up.

Once we decided, in consultation with the patient and her family, to attempt this first-at-UPMC endovascular repair of the ascending aorta, the procedure went smoothly. A stent was placed with access through the femoral artery. There are no stents currently approved by the United States Food and Drug Administration (FDA) specifically for use in the ascending aorta. Off-label use of a thoracic aortic stent graft is the most common approach reported in published cases.<sup>5</sup> We used two 43 x 55 mm covered endografts, which are approved for use in other aortic segments, in an overlapping technique. We routinely use the covered endografts for TEVAR of the thoracic descending aorta and abdominal aortic segments. The patient had a smooth surgical and

postoperative course and was taken off the ventilator at the conclusion of the operation. Her tracheostomy tube was removed two days later. She was discharged 14 days after the procedure and is undergoing routine follow-up at one month, three months, six months, and then yearly. She was evaluated in the clinic one month after discharge and is doing well living at home with her husband and has been caring for herself and enjoying her new lease on life. She is hoping to be evaluated for a kidney transplant. Imaging with computed tomography at her follow-up visit was encouraging, and we continue to do all that we can to get her back to her previous state of health.

The Center for Thoracic Aortic Disease, established by the UPMC Department of Cardiothoracic Surgery, is home to surgeons, cardiologists, and other physicians and professionals dedicated to treating all forms of aortic disease. We have a life-changing combination of resources and research that allows us to expand the boundaries of surgical care in a safe, controlled, and thoughtful way, as exemplified by this case. A new consolidated email process was recently instituted and is meant to guide referrals and assist with any questions about aortic disease simply by emailing [aorticcenter@upmc.edu](mailto:aorticcenter@upmc.edu). Our goal is to become an indispensable resource for community physicians, surgeons, and cardiologists faced with caring for patients with aortic disease. We remain dedicated to our patients and are pushing the envelope to develop the best treatments for aortic disease.

## References

- 1 Sultan I, Dufendach K, Kilic A et al. Bare Metal Stent Use in Type B Aortic Dissection May Offer Positive Remodeling for the Distal Aorta. *Ann Thorac Surg* 2018;106:1364-1370.
- 2 Brown JA, Arnaoutakis GJ, Kilic A, Gleason TG, Aranda-Michel E, Sultan I. Medical and surgical management of acute type B aortic intramural hematoma. *J Card Surg* 2020.
- 3 Plichta RP, Hughes GC. Thoracic endovascular aortic repair for the ascending aorta: experience and pitfalls. *J Vis Surg* 2018;4:92.
- 4 Klonaris C, Georgopoulos S, Katsargyris A. Endovascular treatment of the ascending aorta: new frontiers for thoracic endovascular aneurysm repair? *J Thorac Dis* 2016;8:1901-3.
- 5 Muetterties CE, Menon R, Wheatley GH, 3rd. A systematic review of primary endovascular repair of the ascending aorta. *J Vasc Surg* 2018;67:332-342.
- 6 Roselli EE, Idrees J, Greenberg RK, Johnston DR, Lytle BW. Endovascular stent grafting for ascending aorta repair in high-risk patients. *J Thorac Cardiovasc Surg* 2015;149:144-51.



**Derek R. Serna-Gallegos, MD**

Assistant Professor of Cardiothoracic Surgery

**Ibrahim Sultan, MD, FACS, FACC**

Associate Professor of Cardiothoracic Surgery  
Director, Center for Thoracic Aortic Disease

# Lung Transplantation in the Midst of the COVID Pandemic

by Takashi Harano, MD; Ernest G. Chan, MD MPH; Pablo Sanchez, MD, PhD, FACS

When COVID-19 began to spread in the United States in March 2020, the surgeons at UPMC were concerned. Patients with end-stage lung disease and lung transplant recipients would be particularly vulnerable to COVID-19, as the virus specifically targets the lungs and is associated with increased mortality in immunosuppressed or highly comorbid patients.

In the Division of Lung Transplant and Lung Failure, part of the UPMC Department of Cardiothoracic Surgery, we decided to limit lung transplantation to only the sickest patients, namely patients with a lung allocation score (LAS) of more than 50. At that time, similar to transplant surgeons nationwide, we had many concerns about how the virus would impact our patients and the resources available for their care. It was crucial to determine whether there would be sufficient medical resources, including extracorporeal membrane oxygenation (ECMO), to care for both lung transplant recipients and patients with COVID-19. Additionally, we were concerned that immunosuppression would create a fatal condition if an immunosuppressed patient became infected with COVID-19. We began utilizing telemedicine in place of clinic visits for many patients, including visits for lung transplant referral, waiting list re-evaluation, or follow-up more than 1-year posttransplant.

By end of April 2020, we realized that we could safely make our lung transplant goals more ambitious as long as we could do so while declining lung offers from areas with a high prevalence of COVID-19, Pittsburgh, Allegheny County, and the surrounding counties were not developing into COVID-19 hot spots, in contrast to some areas of the country, including several counties in eastern Pennsylvania. Hospital resources at UPMC, including ECMO resources, were sufficient to treat both lung transplant recipients and patients with COVID-19 who required hospitalization. After reviewing the situation in western Pennsylvania and at

UPMC, we decided to remove our restrictions based on LAS. In April and May, when many lung transplant centers were still limiting transplantation to the sickest patients, UPMC resumed lung transplantation using patient selection criteria similar to those applied before the onset of the COVID pandemic. We developed and closely followed institutional safety protocols to ensure the well-being of both our patients and our staff.

When performing a lung transplant during the COVID pandemic, it is essential to confirm that the donor is not infected with COVID-19. In the early phase of the pandemic, before April 2020, testing was not readily available and confirmation could take up to 24 hours. If testing was unavailable, donors were evaluated for pertinent exposures, such as geographic location, history of travel, and any potential iatrogenic exposure, including the medical staff and physical proximity to a hospital's COVID-19 patients. If the testing or history indicated COVID-19 exposure, offers were declined regardless of graft quality or recipient acuity. As COVID test results became more promptly available, we started to accept lung offers based on more liberal criteria, and we currently can safely accept offers even from high prevalence areas. We also instituted protocols to screen potential lung transplant recipients with a rapid COVID-19 test when they arrive at the hospital, giving results within three hours. Moreover, UPMC requires preoperative COVID-19 screening for all patients who will undergo surgery at our institution, and we query patients for new symptoms that may have developed since their last nasal swab. This reduces the likelihood that our lung transplant recipients will encounter a COVID-positive patient during their hospital stay. Additionally, all UPMC campuses have rigorous COVID-19 safety measures in place, including facility entrance screening with temperature monitoring, requiring facemasks at all times inside all UPMC facilities, restricting visitors and

volunteers, and routinely disinfecting surfaces using hospital-grade disinfectants.

Our patients have benefited from this cautious approach and the efforts of front-line health care workers during the pandemic. As transplant surgeons, we are particularly appreciative of the organ retrieval teams who have been working during the pandemic. These professionals must retrieve organs outside of western Pennsylvania when necessary and must work in hospitals with different protective protocols and access to testing. Our teams have traveled to 18 different states for procurements since mid-March with no transmission of the virus to our staff or patients.

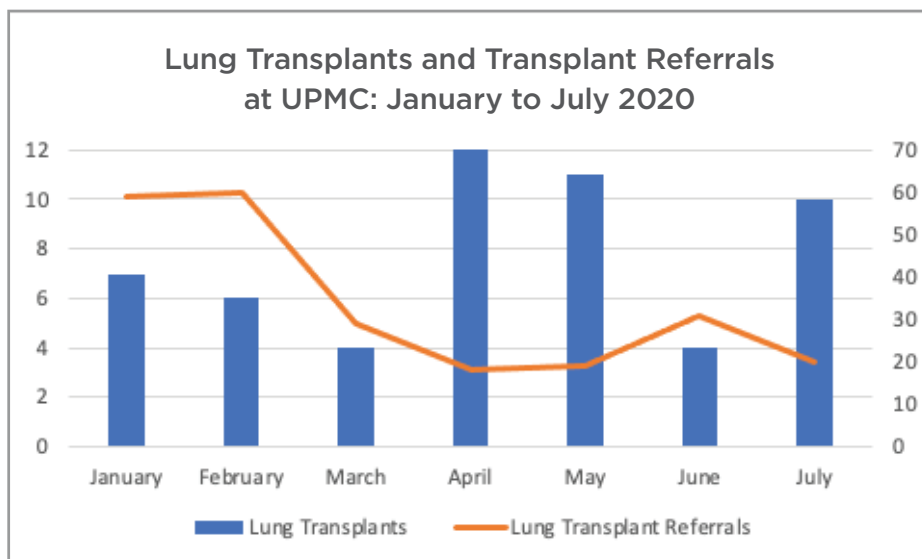
In April and May 2020, we performed 12 and 11 lung transplants, respectively, approximately double our usual volume. We performed 41 lung transplants between March 2020 and July 2020, which is comparable with the same period in 2019. (Figure 1) None of the lung recipients transplanted at UPMC since March 2020 acquired COVID-19 during their hospitalization or posttransplant recovery.

The COVID-19 pandemic has taken a toll on the practice of solid organ transplantation in the United States. From March 6 to April 10, 2020, total organ transplants in the United States decreased 51%. In a study comparing wait list additions, wait list deaths, and transplants performed in April 2020 compared to January and February 2020, the COVID pandemic reduced lung transplants 40% nationwide.<sup>2</sup> In the UNOS mid-Atlantic region where our center is located, the number of adult lung transplants performed in the first half of 2020 drastically decreased by 21.4% as compared with 2019, with an all-time low of two to three transplants weekly in April 2020. Nationally, wait list additions for lung transplant decreased by 34%, and deaths while listed for a lung transplant increased 12%.<sup>2</sup>

Differing from the trends seen nationally and in our UNOS region, mortality for

patients waiting for a lung transplant has been very low at UPMC throughout the pandemic. This is very encouraging as it confirms UPMC can provide first-class, life-changing medicine to patients with end-stage lung disease even during the COVID-19 pandemic. Throughout the summer of 2020, our lung transplant waiting list has been shorter than is typical, however, reflecting the nationwide trends. (Figure 1). Fewer patients with end-stage lung disease were referred to us for evaluation and, therefore, we listed fewer patients. A cautious attitude from patients and their referring physicians seems to be driving this decrease. In an effort to booster our waiting list, all referrals are now seen in person. While we continue to offer telemedicine for routine visits, we can currently safely bring patients who require any testing or procedures into our clinic with COVID-19 testing 48 hours before they arrive at the hospital. We are hopeful that, we will see increased listing and more lung transplants as our outcomes continue to show that transplant can be performed safely in the COVID era with adequate precautions.

COVID-19 posed unprecedented risks for patients with end-stage lung disease and lung transplant recipients. However, due the unforeseeable resolution of the pandemic, the lung transplant community has adapted its practice to safely provide services to patients in need without



**Figure 1.** Monthly lung transplants and lung transplant referrals at UPMC during the first half of 2020. Nationwide changes to transplantation in response to the COVID pandemic began in mid-March 2020.

compromising safety. Community spread of COVID-19 is currently low in western Pennsylvania. As of early October 2020, approximately seven new cases per 100,000 people were reported per day in Allegheny County, and our neighboring counties ranged from four to 17 new cases daily per 100,000 people.<sup>3</sup> Given our extensive experience since March, readily available testing, and established safety protocols, we anticipate that we will continue to offer life-saving lung transplants at UPMC as the COVID-19 pandemic evolves.

### References

- 1 Loupy A, Aubert O, Reese PP, Bastien O, Bayer F, Jacquelinet C. Organ procurement and transplantation during the COVID-19 pandemic. *Lancet*. 2020;395(10237):e95-e96.
- 2 Cholankeril G, Podboy A, Alshuwaykh OS, et al. Early Impact of COVID-19 on Solid Organ Transplantation in the United States. *Transplantation*. 2020.
- 3 Health BUSoP. How severe is the pandemic where you live? *Pandemics Explained 2020*; <https://globalepidemics.org/key-metrics-for-covid-suppression/>.



#### Takashi Harano, MD

Assistant Professor of Cardiothoracic Surgery

#### Ernest G. Chan, MD, MPH

Thoracic Surgery Integrated Resident, PGY4

#### Pablo G. Sanchez, MD, PhD, FACS

Assistant Professor of Cardiothoracic Surgery  
Vice Chairman, Benign Lung Diseases  
Surgical Director, Lung Transplantation and ECMO  
Director, Lung Transplant Research  
Director, Ex Vivo Lung Perfusion (EVLV) Program

# Primary Cardiac Tumors: Surgical Treatment Improves Survival

by Valentino Bianco, DO, MPH; Ibrahim Sultan, MD, FACS

Primary cardiac tumors are extremely rare, comprising just 0.008% of cancer diagnoses in the United States, and patients with primary cardiac malignancy carry a notoriously poor prognosis.<sup>1</sup> Due to the rarity of the malignancy, cardiac surgeons are challenged with determining when to attempt resection in patients with a primary cardiac tumor. Additionally, controversy has arisen, in the absence of clear data, regarding the role of adjuvant therapy in treatment. Moreover, it is difficult to accrue patients to studies at a single institution due to low volume and changing standards of care over time. For these reasons, we undertook a study to examine long-term outcomes of patients with primary cardiac malignancies using the National Cancer Database (NCDB).

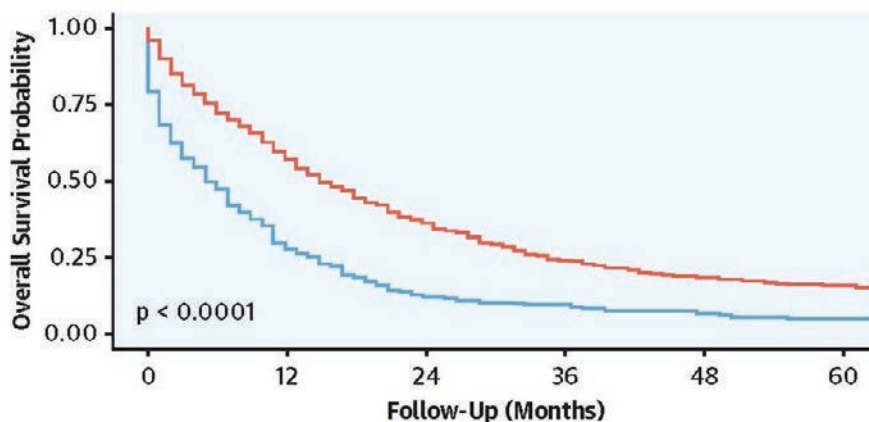
Primary cardiac tumors comprise less than 1% of heart cancer diagnoses; metastases to the heart from distant primary tumors are encountered far more frequently.<sup>2</sup> Most patients present with advanced cancer that is not diagnosed until heart failure and obstructive symptoms manifest due to tumor bulk. Complications of primary cardiac tumors include valve regurgitation and thrombus

formation with heightened embolization risk. When assessing operative candidacy, surgeons should consider the patient's age, comorbidities, and whether distant metastases are present. At UPMC, surgeons in the Division of Adult Cardiac Surgery of the Department of Cardiothoracic Surgery work collaboratively with our colleagues in the Division of Cardiology to reach a consensus on the best treatment approach for patients with primary cardiac tumors.

Our goal in examining the cohort available in the NCDB, which is jointly sponsored by the American College of Surgeons and the American Cancer Society, was to analyze how surgical resection and other treatments affected survival and to better understand the typical profile of patients with a primary cardiac tumor. After excluding patients with heart metastases, benign tumors, and cardiac lymphomas, the cohort consisted of 747 patients with a median age of 53 years who were treated from 2004 to 2016. Most of their tumors were classified as sarcomas (89%). Surgery was performed in 60% of the patients, either alone (187 patients) or as

part of a multimodality treatment plan (255 patients). The study confirmed the dismal prognoses associated with primary malignancy of the heart. The overall survival was 81.2% after 30 days, 45.3% after one year, and just 11.5% after five years. Survival was correlated with tumor stage, and patients with stage I primary cardiac tumors had the best survival. Encouragingly, patients who underwent surgery had significantly better ( $p < 0.001$ ) estimated survival than those who underwent only radiation therapy and/or chemotherapy or who received no treatment (Figure 1). Due to the need to maintain vital heart structure, residual tumor often remains following resection, and an R0 resection was accomplished in only 26.0% of patients, with improved survival in this group (Figure 2). In the subpopulation of patients with stage III disease, patients who underwent surgical resection and then received adjuvant chemotherapy had significantly improved survival as compared with patients who only underwent resection (Figure 3).

Although our study of primary cardiac tumors using the NCDB did not identify treatment center as a factor influencing



— No Surgery  
— Surgery Part of Management

**Figure 1.** Surgery improves long-term survival in patients with primary cardiac tumors. Reprinted from Reference 2. Copyright (2020), with permission from Elsevier.



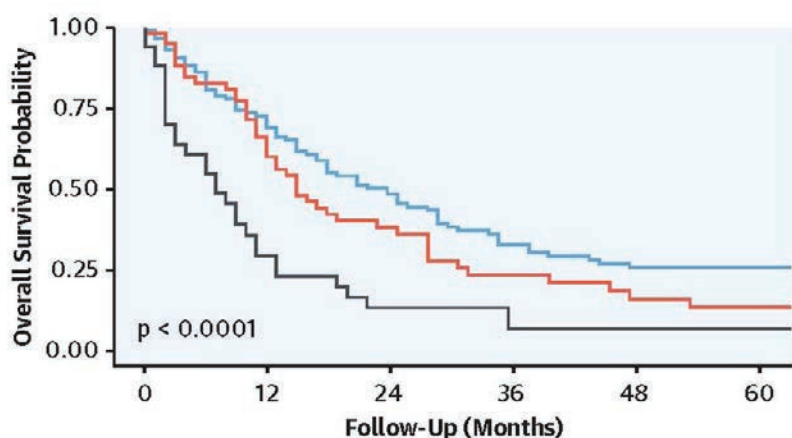
long-term survival, treatment at UPMC, a high-quality tertiary care center, has significant advantages. A multidisciplinary team of oncologists, cardio-oncologists, and cardiothoracic surgeons allows for a 360-degree evaluation of a patient's cardiac tumor. Experienced operating room staff and skilled critical care personnel are invaluable assets when caring for these patients who have complicated needs and high perioperative morbidity. Following assessment by our multidisciplinary team, including evaluation of the final tumor

margins by our expert pathologists, recommendations on the potential benefits of adjuvant therapy are made by knowledgeable oncologists.

This large study performed by our group in the UPMC Department of Cardiothoracic Surgery using a multi-institutional database provides good evidence that carefully selected patients with primary cardiac tumors fare better with early surgical intervention.

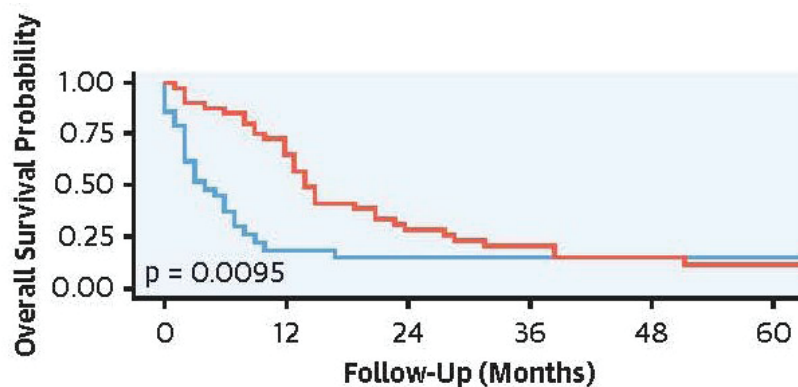
## References

- 1 Oliveira GH, Al-Kindi SG, Hoimes C, Park SJ. Characteristics and Survival of Malignant Cardiac Tumors: A 40-Year Analysis of >500 Patients. *Circulation*. 2015;132(25):2395-2402.
- 2 Tyebally S, Chen D, Bhattacharyya S, et al. Cardiac Tumors. *JACC: CardioOncology*. 2020;2(2):293.
- 3 Sultan I, Bianco V, Habrtheuer A, et al. Long-Term Outcomes of Primary Cardiac Malignancies: Multi-Institutional Results From the National Cancer Database. *J Am Coll Cardiol*. 2020;75(18):2338-2347.



— No Microscopic Margin (R0 Resection)  
 — Microscopic Residual Disease (R1 Resection)  
 — Macroscopic Residual Disease (R2 Resection)

**Figure 2.** An R0 resection is associated with improved long-term survival. Reprinted from Reference 2. Copyright (2020), with permission from Elsevier.



— Stage III: Surgery Alone  
 — Stage III: Surgery with Chemotherapy and/or Radiation

**Figure 3.** In patients with stage III primary cardiac tumors, adjuvant chemotherapy improves long-term survival. Reprinted from Reference 2. Copyright (2020), with permission from Elsevier.



**Valentino J. Bianco III, DO, MPH**  
 Thoracic Surgery Integrated Chief Resident

**Ibrahim Sultan, MD, FACS, FACC**  
 Associate Professor of Cardiothoracic Surgery  
 Director, Center for Thoracic Aortic Disease

# Department News

## The Department of Cardiothoracic Surgery Congratulates Our Team

### Appointments

**Omar Awais, DO**, was appointed program director, Advanced Thoracic Minimally Invasive Fellowship Program, and member-at-large for the Fellowship Board of Directors.

**Inderpal S. Sarkaria, MD, MBA, FACS**, was appointed as Senior Associate Editor of the Clinical Lung Cancer journal. He was also appointed to the AATS Foundation Finance Committee.

### Awards

**Valentino Bianco, DO, MPH (PGY6)**, was awarded the Scientific Contribution Award by the Department of Cardiothoracic Surgery faculty.

**Neil A. Christie, MD; James D. Luketich, MD, FACS; Matthew J. Schuchert, MD, FACS; and Victor O. Morell, MD**, were named 2020 Best Doctors by Best Doctor's Inc., as published by *Pittsburgh Magazine*.

**Neil A. Christie, MD**, and **Pablo G. Sanchez, MD, PhD, FACS**, were co-awarded the Thoracic Surgery Faculty of the Year Award by the University of Pittsburgh Department of Cardiothoracic Surgery residents and fellows.

**Laura M. Seese, MD, MS (PGY4)**, was awarded the Academic Leadership Award by the Department of Cardiothoracic Surgery faculty.

**Ibrahim Sultan, MD, FACS, FACC**, was awarded Outstanding Course Director of a Mini Elective by the University of Pittsburgh School of Medicine.

**Ibrahim Sultan, MD, FACS, FACC**, was awarded the Donald S. Fraley Award for Medical Student Mentoring University of Pittsburgh School of Medicine.

### Grants

**Keith A. Dufendach, MD (PGY4)**, was awarded a \$60,000 grant from the Thoracic Surgery Foundation to study "Weakly Supervised Machine Learning for Automated Transthoracic Echocardiogram Interpretation."

**Rajeev Dhupar, MD, MBA, FACS**, began a \$1,557,884 4-year VA Career Development Award as PI studying ways to improve immunotherapies for patients with malignant pleural effusions.

**Alexandrea Bartow, MSN, ACNP-BC, MBA**, and **Chigozirim Ekeke, MD (PGY4)**, were awarded \$3,600 from the UPMC Beckwith Institute for their project, "Social Rounds: Enhancing Patient Experience with Tech."

**Bryan Yoo, MD, Jim Ackerman, MD, and Leonid Emerel, MD** were awarded \$5,000 from the AATS Graham Robotics Fellowship.

**Adam Soloff, PhD**, was awarded an \$80,000 American Lung Association/Thoracic Surgery Foundation Lung Cancer Research Award as PI to study "Enhancing the Functionality of T cells for Next Generation Adoptive Cell Transfer Therapy for Advanced Lung Cancer."

The Lung Transplantation Laboratory of **Pablo G. Sanchez, MD, PhD, FACS**, and **Kentaro Noda, PhD**, was awarded \$25,000 for the UPMC Vascular Medicine Institute Pilot Project Program in Hemostasis and Vascular Biology (P3HVB).

**Ibrahim Sultan, MD, FACS, FACC**, was awarded a \$705,528 Department of Defense grant as PI to study "Advanced Technology Development for a Secure Wireless Disposable Physiological Monitoring Patch."

### Visiting Professorships

**James D. Luketich, MD, FACS**, was the James B. D. Mark Family Visiting Professor at the Stanford University Department of Cardiothoracic Surgery, where he spoke about "The Evolution of Minimally Invasive Esophagectomy."

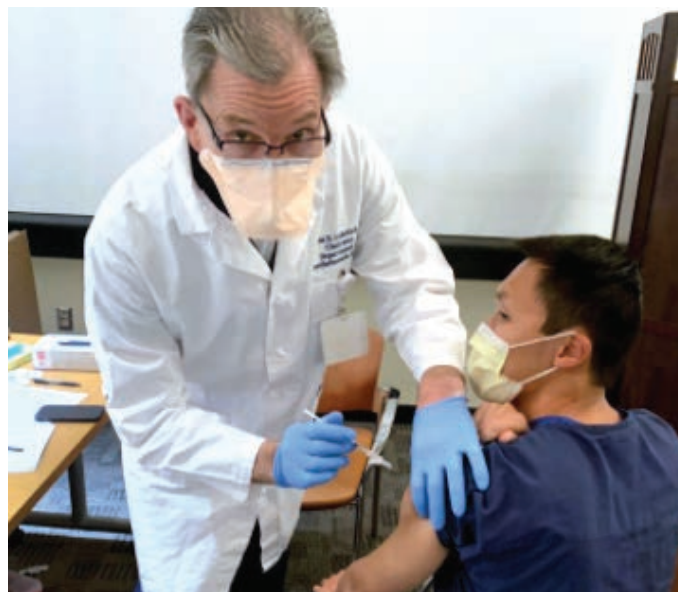### New Clinical Locations

Thoracic Surgery Greensburg Clinic: Omar Awais, DO, and Tadeusz Witek, MD

Thoracic Surgery West Mifflin Clinic: Omar Awais, DO, and Tadeusz Witek, MD

### The Department of Cardiothoracic Surgery's Response to COVID-19

**James D. Luketich, MD, FACS**, lends a helping hand administering COVID-19 vaccinations to UPMC staff."



# Selected Clinical Trials — Department of Cardiothoracic Surgery

## Division of Thoracic and Foregut Surgery

- A Phase III Randomized Trial of Pyloroplasty versus No Pyloroplasty in Patients Undergoing Esophagectomy  
**PI: James Luketich, MD**
- Outcomes after Esophagectomy with a Focus on a Minimally Invasive Esophagectomy and Quality of Life  
**PI: James Luketich, MD**
- A Pilot Study of MUC1 Vaccine in Current and Former Smokers at High Risk for Lung Cancer  
**PI: Arjun Pennathur, MD**
- Study of the Immunogenicity of the MUC1 Peptide-Poly-ICLC in Patients with Localized and Locally Advanced Non-Small Cell Lung Cancer  
**PI: Arjun Pennathur, MD**
- A Phase 3, Randomized, Single dose, Open-Label Study to Investigate the Safety and Efficacy of OTL38 Injection for Intraoperative Imaging of Folate Receptor Positive Lung Nodules  
**PI: Inderpal Sarkaria, MD**
- A Randomized Phase III Study of Sublobar Resection versus Stereotactic Ablative Radiotherapy (SAbR) in High Risk Patients with Stage I Non-Small Cell Lung Cancer (Stable-Mates)  
**PI: James Luketich, MD**
- A Registry for Patients with Multifocal Ground Glass Opacities  
**PI: Arjun Pennathur, MD**
- Study to Evaluate Perioperative Circulating Tumor DNA as a Prognostic Biomarker in Patients Undergoing Neoadjuvant Therapy for Resectable Non-Small Cell Lung Cancer  
**PI: Arjun Pennathur, MD**
- Quantitative Analysis of Barriers to Early Detection of Esophageal Adenocarcinoma  
**PI: Inderpal Sarkaria, MD**
- Detection of Genetic Markers of Lung Cancer Initiation and Progression  
**PI: Arjun Pennathur, MD**
- Esophageal Cancer Risk Registry  
**PI: James Luketich, MD**
- National Mesothelioma Virtual Bank  
**PI: Michael Becich, MD, PhD**
- Collection of Pleural Effusions for Research  
**PI: Rajeev Dhupar, MD**

## Division of Lung Transplant/Lung Failure

- Assessment of Donor Derived Cell Free DNA and Utility in Lung Transplantation  
**PI: Pablo Sanchez, MD, PhD, FACS Sponsor: CareDx**
- Normothermic Ex Vivo Lung Perfusion (EVLP) as an Assessment of Extended/Marginal Donor Lungs  
**PI: Pablo Sanchez, MD, PhD, FACS Sponsor: XVIVO**
- Development of Biorepository to Assess Immune Modulation Following Organ Transplantation  
**PI: Pablo Sanchez, MD, PhD, FACS**

- Lung Failure and Lung Transplant Broad Chart Review  
**PI: Pablo Sanchez, MD, PhD, FACS**
- ECMO Broad Chart Review  
**PI: Pablo Sanchez, MD, PhD, FACS**

## Division of Adult Cardiac Surgery

- Tendyne-Summit: (Clinical Trial to Evaluate the Safety and Effectiveness of Using the Tendyne Mitral Valve System for the Treatment of Symptomatic Mitral Regurgitation)  
**PI: Conrad Smith, MD Sponsor: Abbott**
- Apollo: Transcatheter Mitral Valve Replacement with the Medtronic Intrepid™ TMVR System in patients with severe symptomatic mitral regurgitation – APOLLO Trial  
**Co PI's: Ibrahim Sultan, MD, and Conrad Smith, MD Sponsor: Medtronic**
- WISPR: Study to Assess WiSPR (Wireless Sensing, Processing and Recording) reusable patch in Transcatheter Aortic Valve Replacement (TAVR) patients  
**PI: Ibrahim Sultan, MD Sponsor: Lifeware Labs**
- Tavr Unload: Transcatheter Aortic Valve Replacement to Unload the Left Ventricle in Patients with Advanced Heart Failure: A Randomized Trial (TAVR UNLOAD)  
**PI: Dustin Kliner, MD Sponsor: Avania**
- Reprise IV: REpositionable Percutaneous Replacement of Stenotic Aortic Valve through Implantation of LOTUS Edge™ Valve System in Intermediate Surgical Risk Subjects  
**PI: Ibrahim Sultan, MD Sponsor: Boston Scientific**
- Optimize PRO: Optimize PRO TAVR Post Market Study  
**PI: Ibrahim Sultan, MD Sponsor: Medtronic**
- Cardiac Tissue & Blood Bank Study  
**PI: Ibrahim Sultan, MD**
- Quikclot-: A Pre-Market Prospective, Controlled, Multicenter, Single Blinded, Pivotal Clinical Investigation of QuikClot Control+ for use in Mild to Moderate Bleeding  
**PI: Ibrahim Sultan, MD Sponsor: Z-Medica**
- DT PAS/Apogee: Product Surveillance Registry (PSR) Platform Base Protocol  
**PI: Gavin Hickey, MD Sponsor: Medtronic**
- Atrioventricular Septal Defect – A Congenital Heart Surgeons' Society Inception Cohort Study
- Congenital Heart Surgeons' Society Tricuspid Atresia Study
- Optimal Management of Critical Left Ventricular Outflow Tract Obstruction: A CHSS Study
- Determining the Natural and Unnatural History of Anomalous Aortic Origin of a Coronary Artery with Interarterial or Interconal or Intramural course: Establishing a Multi-Institutional Registry
- Xeltis Bioabsorbable Pulmonary Valved Conduit Early Feasibility Study

# Department of Cardiothoracic Surgery Faculty

## Leadership



**James D. Luketich, MD, FACS**  
*Henry T. Bahnson Professor of Cardiothoracic Surgery*  
*Chairman, Department of Cardiothoracic Surgery*  
*Chief, Division of Thoracic and Foregut Surgery*  
*Director, Thoracic Surgical Oncology*  
*Director, UPMC Esophageal and Lung Surgery Institute*  
*Director, Mark Ravitch/Leon C. Hirsch Center for Minimally Invasive Surgery*



**Victor O. Morell, MD**  
*Eugene S. Wiener Professor of Pediatric Cardiothoracic Surgery*  
*Vice Chair and Director Cardiovascular Services, Department of Cardiothoracic Surgery*  
*Chief, Division of Adult Cardiac Surgery*  
*Chief, Division of Pediatric Cardiothoracic Surgery*  
*Surgeon-In-Chief, UPMC Children's Hospital of Pittsburgh*  
*Executive Director, UPMC Heart and Vascular Institute*  
*Co-Director, Heart Institute, UPMC Children's Hospital of Pittsburgh*

## Division of Adult Cardiac Surgery



**David J. Kaczorowski, MD**  
*Surgical Director, Advanced Heart Failure Center*



**Robert L. Kormos, MD, FAHA, FRCS(C)**



**Ibrahim Sultan, MD**  
*Director, Center for Thoracic Aortic Disease*  
*Co-Director, Center for Transcatheter Aortic Valve Therapies*



**Danny Chu, MD, FACS**  
*Chief, Cardiac Surgery, VAMC of Pittsburgh*



**Forozan Navid, MD**



**Siva P. Venkata, MD**  
*Director, Cardiac Surgery, UPMC Altoona*



**Daniel Ciaburri, MD, FACC, FACS, MBA**



**Julie Phillippi, PhD**  
*UPMC Pellegrini Chair in Cardiothoracic Surgery and Bioengineering*  
*Vice Chair, Cardiac Surgery Research*  
*Director, Post-Doctoral Research*



**David M. West, MD**



**Francis D. Ferdinand, MD**  
*Chief, Cardiac Surgery, UPMC Hamot*



**Derek R. Serna-Gallegos, MD**



**Pyongsoo David Yoon, MD**

## Division of Pediatric Cardiac Surgery



**Luciana Da Fonseca Da Silva, MD**



**Jose Da Silva, MD**  
*Surgical Director, Center for Valve Therapy, UPMC Children's Hospital of Pittsburgh*



**Ergin Kocylidirim, MD**



**Mario Castro Medina, MD**



**Melita Viegas, MD**  
*Director, Pediatric Mechanical Circulatory Support*

## Division of Thoracic and Foregut Surgery



**Omar Awais, DO**  
*Chief, Thoracic Surgery, UPMC Mercy*  
*Director, Advanced Minimally Invasive Thoracic Surgery Fellowship*



**Nicholas Baker, MD**



**Neil A. Christie, MD**  
*Chief, Thoracic Surgery, UPMC Shadyside*



**Lawrence Crist, DO, MBA**



**Rajeev Dhupar, MD, MBA**  
*Chief, Thoracic Surgery, VAMC of Pittsburgh*



**Masashi Furukawa, MD**



**Ryan Levy, MD**  
*Vice Chairman, Community Outreach and Thoracic Expansion*  
*Chief, Thoracic Surgery, UPMC Passavant*



**Arjun Pennathur, MD**  
*Sampson Family Professor in Thoracic Surgical Oncology*



**Inderpal (Netu) Sarkaria, MD, MBA, FACS**  
*Chair in Minimally Invasive Surgery*  
*Vice Chairman, Clinical Affairs*  
*Director, Thoracic Robotic Surgery*  
*Director, Thoracic Surgery Quality and Outcomes*  
*Co-Director, UPMC Esophageal and Lung Surgery Institute*



**Matthew J. Schuchert, MD**  
*Program Director, Thoracic Surgery Residency Programs*



**Diane C. Stollo, MD, FACR, FCCP**



**Christopher Wigfield, MD**  
*Chief, Thoracic Surgery, UPMC Altoona*



**Tadeusz D. Witek, MD**

## Division of Lung Transplant/Lung Failure



**Pablo G. Sanchez, MD, PhD, FACS**  
*Vice Chairman, Benign Lung Diseases*  
*Chief, Division of Lung Transplant and Lung Failure*  
*Surgical Director, Lung Transplantation and ECMO*  
*Director, Lung Transplant Research*  
*Director, Ex Vivo Lung Perfusion (EVLV) Program*



**Takashi Harano, MD**



**Pedro Augusto Reck dos Santos, MD, MSc**

## Not Pictured

Mohammed Al-Abdul Mohsen, MD

## Welcoming New Faculty



**John Brady, DO**, joins the thoracic surgery group at UPMC Pinnacle Harrisburg. Dr. Brady earned his medical degree at Philadelphia College of Osteopathic Medicine. After completing medical school, he completed his general surgery residency at Philadelphia College of Osteopathic Medicine, followed by a cardiothoracic surgery fellowship at the University of Nebraska. Dr. Brady then completed further training with an advanced fellowship at the University of Pittsburgh Department of Cardiothoracic Surgery, under the mentorship of Dr. James D. Luketich. Dr. Brady has a special expertise in minimally invasive surgical techniques and esophageal and foregut procedures. Dr. Brady will be joining the thoracic surgery group at UPMC Pinnacle and bringing thoracic surgical care to the Harrisburg, Pa., community.

**Derek R. Serna-Gallegos, MD**, joins UPMC Shadyside as their newest adult cardiac surgeon. Dr. Serna-Gallegos earned his medical degree at the Keck School of Medicine of the University of Southern California. He then completed his training in general surgery at Cedars-Sinai Medical Center in Los Angeles. Dr. Serna-Gallegos moved to Pittsburgh to complete a fellowship in cardiothoracic surgery, after which he was recruited to stay on as faculty in the Department of Cardiothoracic Surgery and the UPMC Heart and Vascular Institute. Dr. Serna is a past winner of the Department of Cardiothoracic Surgery Clinical Excellence Award, as voted on by departmental faculty. His research and clinical interests include aortic root surgery, transcatheter aortic valve replacement (TAVR), endovascular aortic surgery, and surgery for coronary artery disease. Dr. Serna-Gallegos sees patients at UPMC Presbyterian and UPMC Shadyside.



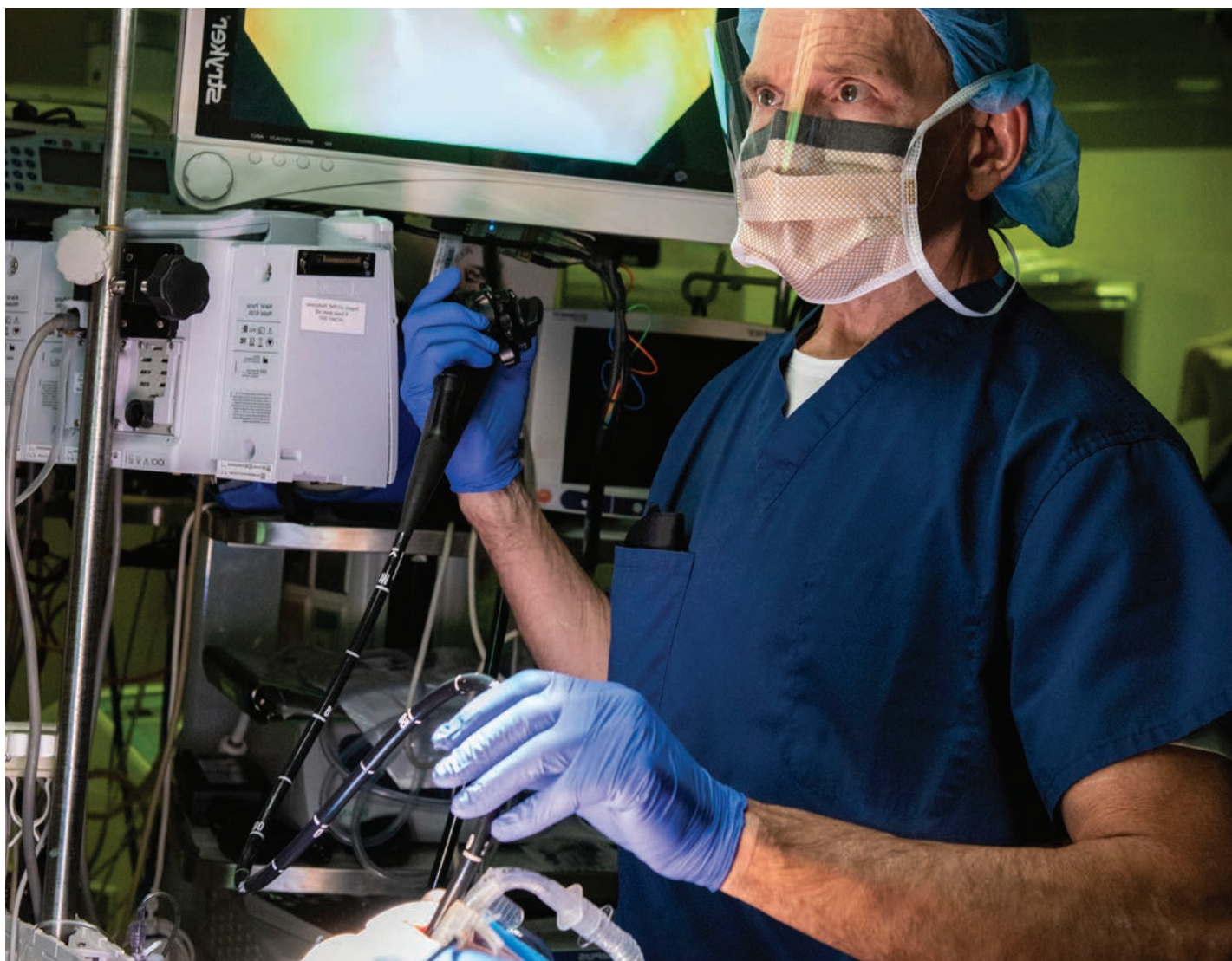**David J. Kaczorowski, MD**, has been appointed to the critical leadership role of surgical director, Heart Transplant/Heart Failure Program. Dr. Kaczorowski earned his medical degree at the Johns Hopkins University School of Medicine. Following medical school, Dr. Kaczorowski completed his general surgery training at the University of Pittsburgh, followed by a cardiothoracic surgery fellowship and then a further advanced fellowship in heart failure and cardiothoracic transplantation at the University of Pennsylvania. After his training, Dr. Kaczorowski spent four years as director of Mechanical Circulatory Support in private practice before being recruited to the University of Maryland School of Medicine. In his three years there, he rose in the ranks to associate professor of surgery and director of Cardiac Transplantation and Mechanical Circulatory Support for the Division of Cardiac Surgery. Dr. Kaczorowski is a member of ISHLT, STS, and AATS.

His research and clinical interests include cardiac transplant, LVAD, and ECMO, as well as resident and fellow education. He holds eight patents and has published more than 50 peer-reviewed articles. Dr. Kaczorowski sees patients at UPMC Presbyterian.

**Tadeusz Witek, MD**, joined UPMC Mercy as their newest thoracic surgeon. Dr. Witek earned his medical degree at Geisinger Commonwealth School of Medicine. He then completed general surgery training at UPMC Mercy, followed by his cardiothoracic surgery training with the UPMC Independent Fellowship Program. Dr. Witek is a recipient of the American Association for Thoracic Surgery Graham Foundation Scholarship for thoracic robotic training, and a past winner of the Department of Cardiothoracic Surgery Clinical Excellence Award, as voted on by the departmental faculty. His research and clinical interests include esophageal surgery, thoracic oncology, and robotic-assisted thoracic surgery. Dr. Witek will be seeing patients at clinic locations at UPMC Mercy, Greensburg, and West Mifflin.



**Christopher Wigfield, MD**, has been recruited to UPMC to lead the thoracic surgery team at UPMC Altoona. Dr. Wigfield studied medicine abroad in Germany and the United Kingdom. He also completed his general surgery and thoracic surgery training in the United Kingdom, followed by an additional cardiothoracic surgery fellowship at the University of Wisconsin. From there, Dr. Wigfield joined the faculty as surgical director of Lung Transplant at Loyola University. He was then recruited to lead the lung transplant team at the University of Chicago, where he rose in the ranks to associate professor of surgery. After a brief tenure with Advocate Christ Medical Center, Dr. Wigfield has joined UPMC to provide surgical care to the Altoona, Pa., community. He has held several past leadership roles with the International Society for Heart and Lung Transplant, and his current clinical and research interests include surgery for malignant and benign lung disease, robotic-assisted thoracic surgery, and professional development for other faculty and trainees.



## UPMC Annual Thoracic CME Series

### **Lung and Mediastinal Oncology Course - *Early Spring***

This course aims to expand clinical knowledge and technical skill regarding the management of cancers of the lung and mediastinum.

### **Minimally Invasive Approaches to the Management of Alachasia and Other Benign Esophageal Diseases - *Late Spring***

This course aims to expand clinical knowledge regarding the treatment of benign esophageal diseases, including gastroesophageal reflux disease (GERD), achalasia, paraesophageal hernia, Zenker's Diverticulum, and Barrett's esophagus.

### **Minimally Invasive Approaches to the Management of Esophageal Cancer - *Late Fall***

This course aims to present the technical aspects of various procedures to treat malignant esophageal conditions, especially minimally invasive esophagectomy (MIE), and its related risks, benefits, and outcomes.

### **Course Coordinator**

**Emily Burgardt**  
UPMC Department of  
Cardiothoracic Surgery  
412-648-6342  
[burgardt@upmc.edu](mailto:burgardt@upmc.edu)

## DEPARTMENT OF CARDIOTHORACIC SURGERY

### About the Department of Cardiothoracic Surgery

The Department of Cardiothoracic Surgery employs more than 35 cardiothoracic surgeons and over 170 professional staff members across four divisions:

- Division of Adult Cardiac Surgery
- Division of Pediatric Cardiothoracic Surgery
- Division of Thoracic and Foregut Surgery
- Division of Lung Transplant/Lung Failure

Our cardiothoracic surgeons lead the way in developing new minimally invasive surgical techniques for treating diseases and disorders of the heart, lungs, esophagus, and mediastinum. Surgeons from around the world learn these techniques through ACGME-accredited residency and fellowship programs, non-ACGME accredited advanced fellowships, and our international observership program.

A national leader in cardiothoracic surgery, UPMC is a pioneering center for minimally invasive surgical techniques for treating esophageal and lung cancers. UPMC has the most extensive minimally invasive esophagectomy experience in the United States.

Our cardiothoracic transplant surgeons have performed more than 3,500 heart, lung, and combined heart-lung transplants since the program's inception. And we continue to innovate and pioneer new techniques in robotic surgery, artificial heart implantation, and development of artificial heart-assist devices.

Our comprehensive range of diagnostic and treatment modalities, along with the continued development of these innovative techniques, allow us to deliver the highest quality care for a full range of cardiothoracic diseases and disorders — including complex cases turned down at other centers.

**A Resource for You:** UPMC Physician Resources brings world-class physicians and free educational opportunities to your computer. Learn new information while watching CME-accredited videos in the convenience of your home or office. Find out more at [UPMCPhysicianResources.com/ThoracicSurgery](http://UPMCPhysicianResources.com/ThoracicSurgery).

To learn more about the UPMC Department of Cardiothoracic Surgery, please visit [UPMCPhysicianResources.com/ThoracicSurgery](http://UPMCPhysicianResources.com/ThoracicSurgery).

UPMC  
PHYSICIAN RESOURCES

### Contact the UPMC Department of Cardiothoracic Surgery at:

#### Division of Adult Cardiac Surgery

412-648-6200  
UPMC Presbyterian  
200 Lothrop St., Suite C-700  
Pittsburgh, PA 15213

#### Division of Pediatric Cardiac Surgery

412-692-5218  
UPMC Children's Hospital of Pittsburgh  
4401 Penn Ave., 5th Floor  
Pittsburgh, PA 15224

#### Division of Thoracic and Foregut Surgery

412-647-7555  
UPMC Presbyterian  
200 Lothrop St., Suite C-800  
Pittsburgh, PA 15213

#### Division of Lung Transplant/Lung Failure

412-648-6315  
UPMC Presbyterian  
200 Lothrop St., Suite C-900  
Pittsburgh, PA 15213

A \$23 billion health care provider and insurer, Pittsburgh-based UPMC is inventing new models of patient-centered, cost-effective, accountable care. The largest nongovernmental employer in Pennsylvania, UPMC integrates 92,000 employees, 40 hospitals, 800 doctors' offices and outpatient sites, and a more than 4 million-member Insurance Services Division, the largest medical insurer in western Pennsylvania. In the most recent fiscal year, UPMC contributed \$1.7 billion in benefits to its communities, including more care to the region's most vulnerable citizens than any other health care institution, and paid more than \$900 million in federal, state, and local taxes. Working in close collaboration with the University of Pittsburgh Schools of the Health Sciences, UPMC shares its clinical, managerial, and technological skills worldwide through its innovation and commercialization arm, UPMC Enterprises, and through UPMC International. *U.S. News* consistently ranks UPMC Presbyterian Shadyside among the nation's best hospitals in many specialties and ranks UPMC Children's Hospital of Pittsburgh on its Honor Roll of America's Best Children's Hospitals. For more information, go to [UPMC.com](http://UPMC.com).