



REHAB Professionals

High-Resolution Ultrasound: A Sports Medicine Doctor's Stethoscope

Kentaro Onishi, DO, Assistant Professor, Department of Physical Medicine and Rehabilitation

Elmar Herbst, MD, Research Fellow, Department of Orthopaedic Surgery

Freddie H. Fu, MD, Chair and David Silver Professor, Department of Orthopaedic Surgery

Musculoskeletal Ultrasound as a Clinical Evaluation Tool

Ultrasound (US) represents a cost-effective (predicted savings of \$6.9 billion when appropriate substitution is made for musculoskeletal US in place of MRI over a 14-year period, and approximately one third to one fifth of the cost to the patients per Medicare¹⁷), readily available diagnostic imaging modality that has gained popularity in musculoskeletal and sports medicine to evaluate a variety of clinical conditions.

Definite technological limitations exist, including narrow field of view, inability to visualize through dense structures such as bony cortex, and decreased resolution for patients with large body habitus due to beam attenuation.

However, advantages include real-time image generation that allows examination of dynamic pathologies, such as snapping hip secondary to iliopsoas or ischiofemoral impingement, or evaluation of meniscus displacement with weight bearing, valgus, or varus stress. Ultrasounds' continuous imaging ability also is an advantage in visualization of small injuries, such as focal fusiform swelling of a peripheral nerve. Precisely placed US-guided diagnostic ultrasound also can be extremely helpful in establishing a correct diagnosis.

Sports medicine clinicians have described musculoskeletal US as the stethoscope of sports medicine/orthopaedic physicians, and our experience is that when US is used as a complement to careful history and physical examinations, musculoskeletal US can assist in accurate, expeditious confirmation of clinical suspicion and timely treatment planning.

Anterolateral Complex of the Knee

Anterolateral Knee Anatomy

Recently, the anterolateral ligament (ALL) of the knee attracted much attention after its description in 2013.⁷ However, in the following years conflicting findings in terms of its presence, insertion site, morphology as well as biomechanical role have been found. Some authors suggest it is an important contributor to restrain internal tibial rotation and therefore the pivot shift phenomenon.²⁰ However, others found the ALL to play a negligible role in knee biomechanics and kinematics. Additionally, some surgeons raised the suspicion that the reconstruction

Continued on Page 2

High-Resolution Ultrasound *(Continued from Page 1)*

of this ligament may lead to overconstraint of the knee, leading to premature degenerative changes of the knee.^{7,14,19,22}

Our laboratories have undertaken a multidisciplinary approach to further understand anterolateral knee structures with studies including embryological, histological, biomechanical, and imaging.^{8,11,16,18} Layer-by-layer cadaveric dissections using 20+ fresh frozen specimens also have contributed to our current knowledge base, and we have observed that there is no consistent or discrete ligamentous structures in the location previously described. Instead, we observed a previously well-described capsulo-osseous layer (COL) of iliotibial band joining with fascia of the short head of biceps femoris creating a sheet-like knee joint capsule, combining to form what might have appeared ligamentous on embalmed specimens due to expected tissue hardening (Figures 1a and 1b). As such, we felt anterolateral complex (ALC = COL + biceps femoris fascia) was a more appropriate term than ALL when referring to anterolateral knee stabilizers.

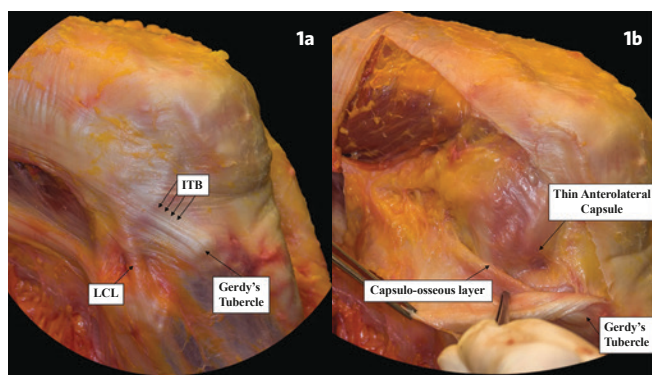


Figure 1a. (left) Dissection of the anterolateral aspect of the knee, showing the superficial layer of the ITB, its relationship with the LCL, and the distal broad attachment to Gerdy's tubercle.

Figure 1b. (right) After reflection of the superficial layer of the ITB, a thin anterolateral capsule is identified. The posterior aspect of the ITB merges with the deeper layer, forming the capsulo-osseous layer.

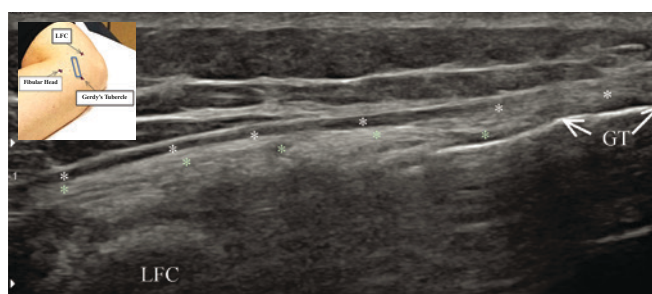


Figure 2. Inset picture showing approximate transducer positioning. Note regional bony landmarks have been marked with a marker on the skin. Sonographic image is the corresponding ultrasound picture at 90° of knee flexion. We typically scan the posterior half of Gerdy's tubercle to find hyper-echoic, bright structure deep to posterior iliotibial band to find anterolateral complex. Transverse view is also obtained but omitted from this article due to space constraint. Left: proximal. Right: distal. LFC: lateral femoral condyle, GT: Gerdy's tubercle, White asterisk: posterior iliotibial band, Green asterisks: anterolateral complex.

Sonographic Evaluation of Anterolateral Complex of the Knee

With anatomic understanding as the basis for further characterization of the ALC, we have endeavored to visualize this complex using high-resolution ultrasound (18-4 MHz linear array transducer, RS80 Prestige, Samsung Medison, Seoul, South Korea). We have sonographically examined more than 50 ALCs in ACL-deficient knees in our patients at various knee angles, using contralateral knees as the control, and we observed expected sono-anatomy based on our anatomic dissection (Figure 2).

Additionally, with increased knee flexion and internal tibial rotations, we have observed improved sonographic visualization of ALCs. This is consistent with our cadaveric observation of increased thickening of ALCs with both knee flexion and internal tibial rotation movements (see Figures 3a and 3b on Page 3).

Sonographic Evaluation of Segond Fracture

Originally described by a French surgeon in 1879, Segond fracture was recently described to be secondary to an avulsion injury of ALL.⁶ Our sonographic observation of one Segond fracture case showed the attachment contributed from two discrete structures. The attached components were 1) COL of the ITB distally and anteriorly on the fragment, and 2) anterolateral capsule of the knee proximally and posteriorly (see Figure 4 on Page 3). This was subsequently confirmed with intra-operative observation (see Figures 5a, 5b, and 5c on Page 3).

Meniscus Subluxation Index

Hoop Tension Mechanism

Meniscus injuries are common among adults of all ages.^{10,12} The role of the meniscus in ensuring normal knee function is multifactorial, but the ability of the meniscus to dissipate axial load through the "hoop tension mechanism" is of particular importance as the loss of this function inevitably leads to osteoarthritis (OA).^{3,9,13,23} The hoop tension mechanism is normally maintained by the anterior and posterior meniscal roots, as well as by interwoven fibers of the body that connect two roots.^{3,13,21} Injury to the meniscus can disrupt its hoop tension mechanism and lead to the radial displacement of the meniscus, a phenomenon known as meniscal extrusion (ME) or meniscal subluxation (MS).^{2,15}

Although medial ME of > 3.0mm and/or lateral ME of > 1.0mm are considered abnormal and have been associated with knee OA, a causal relationship between ME and OA development has not been prospectively established.⁴ Choi et al. recently reported that a high meniscal subluxation index (MSI), represented by the ratio of ME to total meniscal width as measured on coronal plane magnetic resonance imaging (MRI), predicted the development of structural OA in a cohort of 56 patients without MRI evidence of OA at baseline⁵ (see Figure 6 on Page 4).

Sonographic Evaluation of Meniscus

As for sonographic evaluation of the meniscus, Akatsu et al. recently reciprocated results similar to previous investigations on direct visualization of meniscal injuries using sonography, and reported a sensitivity of 88% and a specificity of 85% while scanning 134 menisci.¹ Most early US studies have focused on direct visualization of meniscus lesions, but no study had investigated the ability of US to visualize the internal margin of the meniscus.

Continued on Page 4

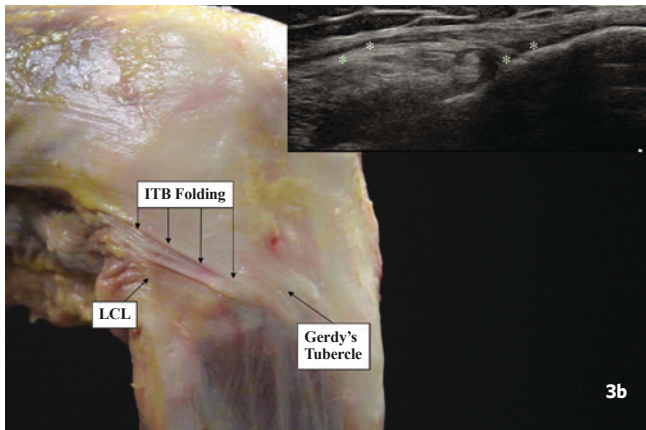
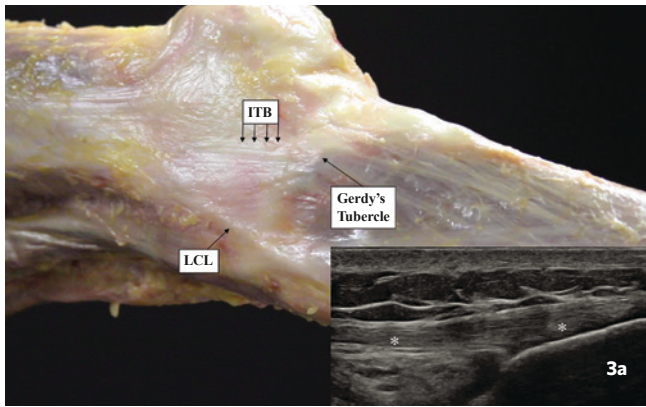


Figure 3a. (top) Lateral aspect of the right knee at 20° of flexion. Note no conspicuous ligamentous structure is noted in space posterior to iliotibial band (ITB) and anterior to lateral collateral ligament (LCL) on the cadaveric specimen or sonographic image. ITB (white asterisks) is obvious. Left side of the image: proximal; Right side of the image: distal.

Figure 3b. (bottom) Lateral aspect of the right knee at 90° of flexion with maximum tibial internal rotation. Note visible folding appears at anterolateral knee region. This corresponds with sonographic thickening of anterolateral complex (green asterisks) with overlaying posterior iliotibial band (white asterisks). Left side of the image: proximal. Right side of image: distal.

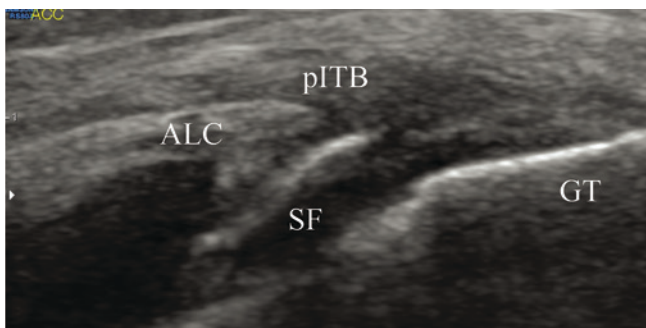


Figure 4. Magnified oblique long axis view of insertional posterior iliotibial band with Segond fragment at 90° of knee flexion. Left side of image: proximal-posterior. Right side of image: distal-anterior. ALC: anterolateral complex of the knee; SF: Segond fragment; pITB: posterior iliotibial band; GT: Gerdy's tubercle.

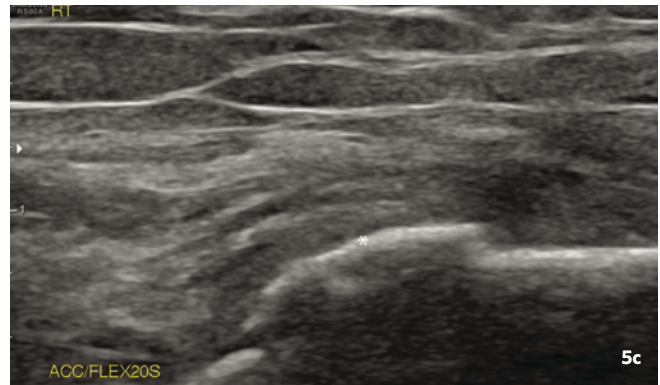
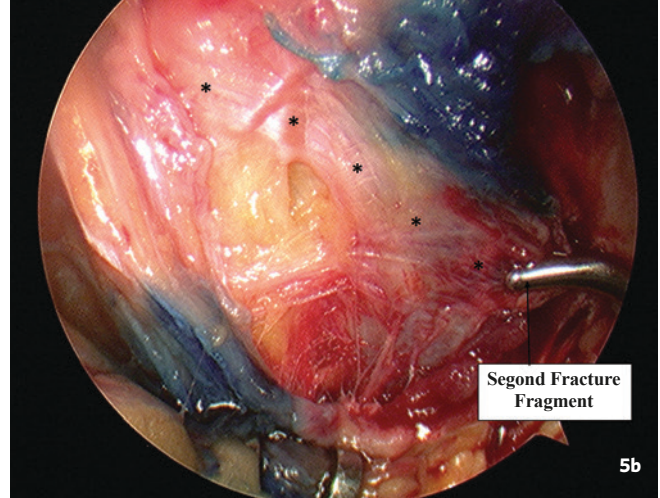
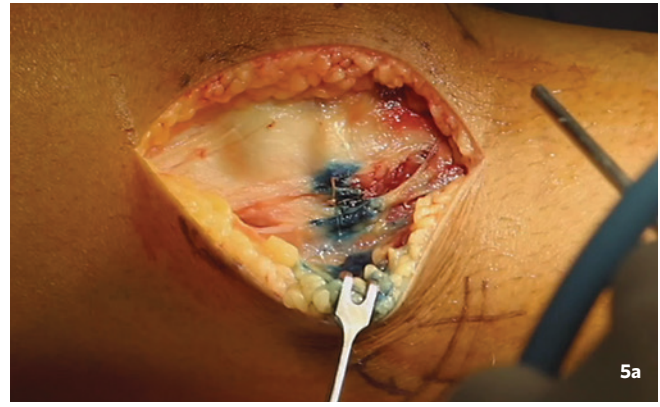


Figure 5a. (top) Lateral approach showing the ITB longitudinally incised over the sonographically-guided methylene blue injection to the Segond fracture site.

Figure 5b. (middle) Intra-operative lateral view of the knee with visible anterolateral knee complex (*) inserting to the Segond Fracture fragment. Sonographically-guided methylene blue injection was performed prior to operation for improved accuracy in identifying the fragment.

Figure 5c. (bottom) 3-month Postoperative image of Segond fragment being successfully reduced/proximated to donor site. Magnified oblique long axis view of insertional posterior iliotibial band with Segond fragment at 90° of knee flexion. Left side of image: proximal-posterior. Right side of image: distal-anterior.

High-Resolution Ultrasound *(Continued from Page 2)*

A recent investigation in collaboration with The Mayo Clinic Sports Medicine (Rochester) attempted to sonographically measure meniscus width (Figure 7) and compared the measurements to anatomic measurements using unembalmed cadaveric specimens. Preliminary results showed a mean margin of error of less than 0.4mm, allowing fairly accurate calculation of MSI.

Although extrapolating results from a cadaveric investigation to diverse clinical populations requires caution, the result from this investigation supports the use of US to functionally evaluate the ME/MS and to calculate MSI to assist in determining incompetent, surgical meniscus.

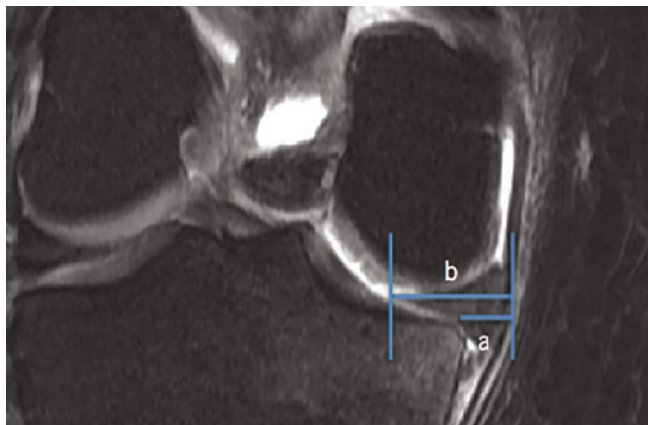


Figure 6. Coronal T2 MRI image of medial meniscus extrusion. Image taken in the mid-coronal plane deep to the medial collateral ligament. Meniscal subluxation index (MSI) = a/b . In this case, the MSI = 0.40. MRI courtesy of Naveen Murthy, MD, Mayo Clinic.

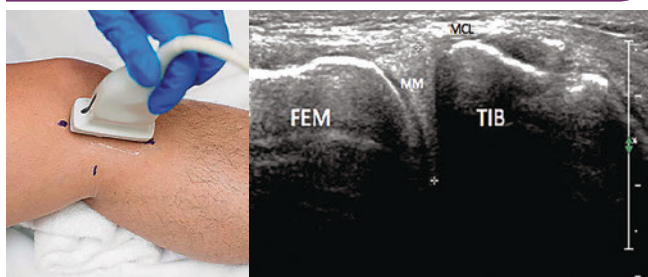


Figure 7. Probe position for short axis sonographic medial meniscus width measurements with corresponding sonographic image. Electronic calipers are seen in sonographic image placed at the outer and inner meniscal margins. FEM = femur; TIB = tibia; MM = medial meniscus; MCL = medial collateral ligament. Images courtesy of Jay Smith, MD, Mayo Clinic.

References

- Akatsu Y, Yamaguchi S, Mukoyama S, et al. Accuracy of High-resolution Ultrasound in the Detection of Meniscal Tears and Determination of the Visible Area of Menisci. *J Bone Joint Surg Am.* 2015; 97(10): 799-806.
- Badlani JT, Borrero C, Golla S, Harner CD, Irrgang JJ. The Effects of Meniscus Injury on the Development of Knee Osteoarthritis: Data From the Osteoarthritis Initiative. *Am J Sports Med.* 2013; 41(6): 1238-1244.
- Bessette GC. The Meniscus. *Orthopedics.* 1992; 15(1): 35-42.
- Brody JM, Lin HM, Hulstyn MJ, Tung GA. Lateral Meniscus Root Tear and Meniscus Extrusion With Anterior Cruciate Ligament Tear. *Radiology.* 2006; 239(3): 805-810.
- Choi YR, Kim JH, Chung JH, et al. The Association Between Meniscal Subluxation and Cartilage Degeneration. *Eur J Orthop Surg Traumatol.* 2014; 24(1): 79-84.
- Claes S, Luycckx T, Vereecke E, Bellemans J. The Segond Fracture: A Bony Injury of the Anterolateral Ligament of the Knee. *Arthroscopy.* 2014; 30(11): 1475-1482.
- Claes S, Vereecke E, Maes M, Victor J, Verdonk P, Bellemans J. Anatomy of the Anterolateral Ligament of the Knee. *J Anat.* 2013; 223(4): 321-328.
- Dombrowski ME, Costello JM, Ohashi B, et al. Macroscopic Anatomical, Histological and Magnetic Resonance Imaging Correlation of the Lateral Capsule of the Knee. *Knee Surg Sports Traumatol Arthrosc.* 2016; 24(9): 2854-2860.
- Fithian DC, Kelly MA, Mow VC. Material Properties and Structure-function Relationships in the Menisci. *Clin Orthop Relat Res.* 1990; (252): 19-31.
- Greis PE, Bardana DD, Holmstrom MC, Burks RT. Meniscal Injury: I. Basic Science and Evaluation. *J Am Acad Orthop Surg.* 2002; 10(3): 168-176.
- Guenther D, Rahnama-Azar AA, Fu FH, Debski RE. The Biomechanical Function of the Anterolateral Ligament of the Knee: Letter to the Editor. *Am J Sports Med.* 2015; 43(8): NP21-22.
- Jones JC, Burks R, Owens BD, Sturdivant RX, Svoboda SJ, Cameron KL. Incidence and Risk Factors Associated With Meniscal Injuries Among Active-duty US Military Service Members. *J Athl Train.* 2012; 47(1): 67-73.
- Jones RS, Keene GC, Learmonth DJ, et al. Direct Measurement of Hoop Strains in the Intact and Torn Human Medial Meniscus. *Clin Biomech (Bristol, Avon).* 1996; 11(5): 295-300.
- Kennedy MI, Claes S, Fusco FA, et al. The Anterolateral Ligament: An Anatomic, Radiographic, and Biomechanical Analysis. *Am J Sports Med.* 2015; 43(7): 1606-1615.
- Kim JG, Lee YS, Bae TS, et al. Tibiofemoral Contact Mechanics Following Posterior Root of Medial Meniscus Tear, Repair, Meniscectomy, and Allograft Transplantation. *Knee Surg Sports Traumatol Arthrosc.* 2013; 21(9): 2121-2125.
- Musahl V, Rahnama-Azar AA, Costello J, et al. The Influence of Meniscal and Anterolateral Capsular Injury on Knee Laxity in Patients With Anterior Cruciate Ligament Injuries. *Am J Sports Med.* 2016. Epub ahead of print.
- Parker L, Nazarian LN, Carrino JA, et al. Musculoskeletal Imaging: Medicare Use, Costs, and Potential for Cost Substitution. *J Am Coll Radiol.* 2008; 5(3): 182-188.
- Rahnama-Azar AA, Miller RM, Guenther D, et al. Structural Properties of the Anterolateral Capsule and Iliotibial Band of the Knee. *Am J Sports Med.* 2016; 44(4): 892-897.
- Schon JM, Moatshe G, Brady AW, et al. Anatomic Anterolateral Ligament Reconstruction of the Knee Leads to Overconstraint at Any Fixation Angle. *Am J Sports Med.* 2016. Epub ahead of print.
- Sonnery-Cottet B, Thunat M, Freychet B, Pupim BH, Murphy CG, Claes S. Outcome of a Combined Anterior Cruciate and Anterolateral Ligament Reconstruction Technique With a Minimum 2-Year Follow-up. *Am J Sports Med.* 2015; 43(7): 1598-1605.
- Starke C, Kopf S, Grobel KH, Becker R. The Effect of a Nonanatomic Repair of the Meniscal Horn Attachment on Meniscal Tension: A Biomechanical Study. *Arthroscopy.* 2010; 26(3): 358-365.
- Tashman S, Kolowich P, Collon D, Anderson K, Anderst W. Dynamic Function of the ACL-Reconstructed Knee During Running. *Clin Orthop Relat Res.* 2007; 454: 66-73.
- Voloshin AS, Wosk J. Shock Absorption of Meniscectomized and Painful Knees: A Comparative In Vivo Study. *J Biomed Eng.* 1983; 5(2): 157-161.

UPMC PHYSICIAN RESOURCES

A Resource for You: UPMC Physician Resources brings world-class physicians and free educational opportunities to your computer. Learn new information while watching CME-accredited videos in the convenience of your home or office. Find out more at UPMCPhysicianResources.com/Rehab.

UPMC Department of Physical Medicine and Rehabilitation
Pittsburgh, PA

Gwendolyn Sowa, MD, PhD
Chair

ADDRESS CORRESPONDENCE TO:
Michael C. Munin, MD
Senior Editor

Kaufmann Medical Building, Suite 201
Pittsburgh, PA 15213
muninmc@upmc.edu