

UPMC REHAB GRAND ROUNDS

WINTER 2019



Accreditation Statement

The University of Pittsburgh School of Medicine is accredited by the Accreditation Council for Continuing Medical Education (ACCME) to provide continuing medical education for physicians.

The University of Pittsburgh School of Medicine designates this enduring material for a maximum of .5 AMA PRA Category 1 Credits™. Each physician should only claim credit commensurate with the extent of their participation in the activity. Other health care professionals are awarded .05 continuing education units (CEU), which are equivalent to .5 contact hours.

Disclosures

Drs. Lueders, Lloyd, and Sherrier report no relationships with proprietary entities producing health care goods and services.

Instructions

To take the CME evaluation and receive credit, please visit UPMCPhysicianResources.com/Rehab and click on the course *Rehab Grand Rounds Winter 2019*.


Affiliated with the University of Pittsburgh School of Medicine, UPMC Presbyterian Shadyside is ranked among America's Best Hospitals by *U.S. News & World Report*.

Demystifying and Defining the “Sports Hernia”



DANIEL R. LUEDERS, MD

*Assistant Professor, Department of Physical Medicine and Rehabilitation
University of Pittsburgh School of Medicine*



ALEXANDER LLOYD, MD

*Resident Physician, Department of Physical Medicine and Rehabilitation
University of Pittsburgh School of Medicine*



MATTHEW SHERRIER, MD

*Resident Physician, Department of Physical Medicine and Rehabilitation
University of Pittsburgh School of Medicine*

Clinical Vignette

AD is a 20-year-old rugby player without previous injury or significant past medical history who presented for evaluation of right groin pain of six-weeks' duration. His pain travels over the adductor musculature, pubis, and lower abdominal region. He plays for his university club rugby team. These symptoms began gradually during the rugby season without distinct trauma.

He has applied ice and taken oral nonsteroidal anti-inflammatory medications (NSAIDs) after practices and games. He worked with his team trainer who performed soft tissue massage and stretching, which made the symptoms bearable to permit play. However, the symptoms have gradually progressed to affect his ability to cut and push off with running. He rested from practices and gameplay for two weeks, but the groin pain reoccurred upon resuming sprinting and cutting activities in practices.

Physical examination identified tenderness over the right adductor longus, pubis, and lower rectus abdominis. Lower limb strength and sensation were normal, and pain was present with resisted right hip adduction and resisted sit-up. He presented to the UPMC Physical Medicine and Rehabilitation Sports Medicine clinic hoping to find a solution to this lingering problem.

Consults and Referrals: For consults and referrals, please call UPMC's 24-hour physician OnDemand service at **1-866-884-8579**.

UPMC
LIFE CHANGING MEDICINE

Definition of the Problem

Injury to the musculoskeletal structures of the groin comprise 2 to 8 percent of all athletic injuries¹ and can result in significant morbidity, trailing only fracture and anterior cruciate ligament (ACL) reconstruction in lost training and playing time.^{2,3} Such injuries are more common in men under the age of 40 and are more prevalent in sports that involve rapid directional changes, accelerations, and hyperextension/hyperabduction movements, such as soccer, football, ice hockey, and baseball.^{4,5} Other risk factors include inadequate or incomplete rehabilitation after a previous musculoskeletal groin injury, higher level of play, decreased hip adduction strength, and lower levels of sport-specific training.^{5,6}

Although a common complaint, musculoskeletal groin pain is diagnostically challenging. The proximity of interrelated musculature and the complex biomechanics of the pubic symphysis, pelvis, and hip joint introduce a large number of potential pain generators in a small anatomic location, making a precise history and physical examination both essential and technically challenging.^{1,5,7}

Musculoskeletal groin pain in the athlete goes by many nonspecific and often vague or anatomically misleading terms. Athletic pubalgia, Gilmore's groin, sportsman's hernia, sports groin pain, osteitis pubis, hockey goalie syndrome, adductor tendinopathy, and enthesopathy are some examples.^{5,7-9} "Sports hernia" is one of the more common terms used, particularly in media and lay publications, but is misleading by implying herniation or fascial wall weakness, which are not always present.¹⁴

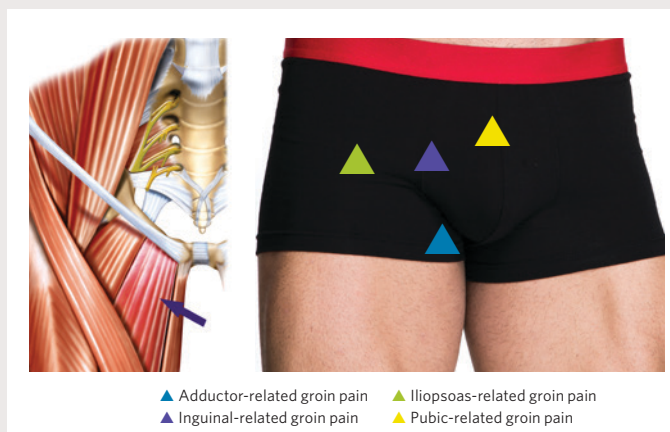

Figure 1. Osseous and musculotendinous anatomy of the groin and palpation examination correlate.

Additional Causes of Groin Pain in Athletes

- **Orthopaedic:** Hamstring strain, Sacroiliitis, Osteoarthritis, Septic arthritis, Avascular necrosis, Osteomyelitis, Snapping hip syndrome, Stress fracture (Femoral neck, Pubic ramus, Acetabulum)
- **Neurological:** Nerve entrapment syndromes (Ilioinguinal, Obturator, Genitofemoral, Iliohypogastric)
- **Rheumatological:** Spondyloarthropathies (Ankylosing spondylitis)
- **Urological:** Urinary tract infection, Nephrolithiasis, Testicular torsion, Prostatitis, Epididymitis, Orchitis
- **Gynecological:** Endometriosis, Pelvic inflammatory disease
- **Gastrointestinal:** Inflammatory bowel disease, Appendicitis, Diverticulitis
- **Oncological:** Osteoid osteoma, Testicular carcinoma, Prostate cancer, Urinary tract cancer, Inguinal lymphadenopathy
- **Surgical:** Inguinal hernia, Abdominal hernias, Post-hernioplasty pain

Table 1. Miscellaneous conditions causing groin pain in athletes.

The phrase “groin pain in the athlete” has been proposed by a panel of internationally recognized athletic groin pain experts as part of the “Doha agreement,” which proposed standardizing terminology and definitions.⁵ The defined clinical entities for groin pain include adductor-related, iliopsoas-related, inguinal-related, and pubic-related pain generators, and are illustrated in Figure 1. Hip-related groin pain represents an additional challenge for clinicians since it can be difficult to distinguish from these other etiologies.⁵ Hip disorders that may cause groin pain include acetabular labral tears, synovitis, osteoarthritis, and intra-articular bodies.¹ The final category that may result in groin pain is reserved for “other etiologies,” including orthopaedic, neurological, rheumatological, urological, gynecological, gastrointestinal, oncological, and surgical causes. See Table 1.⁵

Developing a systematic approach leads to a clear, definitive diagnosis that guides subsequent workup.^{5,7,10,11} The approach delineated at the Doha conference presents a straightforward method to understand the most important anatomy.^{5,7}

Approach to the Physical Examination

Adductor-related Pain

Adductor musculotendinous pathology will often be tender to palpation over the adductor muscle mass in the medial groin and tracking to the pubic symphysis, implicating adductor pathology and localizing symptoms to the course of a tendon or muscle. Common locations of injury are at the proximal adductor origin at the pubis and the myotendinous junctions.⁷ When magnetic

resonance imaging (MRI) is used as a gold standard for findings of adductor pathology, certain maneuvers yield good diagnostic accuracy. Specifically, the absence of tenderness with palpation of the adductor musculature has a high negative predictive value (91 to 96 percent), and pain with resisted adduction at the end-range of abduction motion or a positive adductor squeeze test have a positive predictive value of 80 to 81 percent.⁷⁻¹²

Pubic-related Pain

Pubic-related pain refers to the pubic symphysis and the bony anatomy directly adjacent to it, and includes pubic rami stress fractures, pubic apophysitis, osteitis pubis, and tendinosis or tearing of the rectus abdominis.^{5,7,10} The primary goal of examination is to assess whether a stress fracture may be present since its management differs significantly from the active approach used for other types of groin or pubic-related pain. Otherwise, adductor and pubic-related pain are similar in clinical presentation and can be treated similarly.⁷

Inguinal-related Pain

“Inguinal pain” in the athlete encompasses groin pain in the inguinal canal or pain with Valsalva/coughing/sneezing without palpable herniation on exam to indicate tissue herniation.^{5,7} Abdominal muscle activation, such as a sustained sit-up position, will generally exacerbate symptoms in this region.^{7,13} The exact mechanism of pain is still poorly understood. One theory is that inguinal pain results from a defect or weakness in the posterior abdominal wall that leads to impingement of the femoral branch of the genitofemoral nerve and secondary adductor dysfunction caused by dysfunctional movement and insufficient core stability to counteract the shear forces of torsional movements.^{7,14-17} Additional potential etiologies include conjoint tendon damage, inguinal ligament tearing, or external ring dilation.^{7,18,19}

Direct and indirect inguinal hernias can cause inguinal pain and are associated with a palpable tissue defect and bulge. It is important to note that true hernias can present concurrently, but they are less likely to be specifically sports-related and are beyond the scope of this review.¹⁵

Iliopsoas-related Pain

Tenderness to palpation lateral to the adductor tendons but medial to the anterior inferior iliac spine (AIIS) suggests iliopsoas pain. Tenderness can occur both above and below the inguinal ligament as the psoas myotendinous junction begins superior to the inguinal ligament. Passive stretch of the tendon in hip extension and resisted hip flexion can reproduce

symptoms.^{5,7} Rectus femoris pathology is assessed with resisted hip flexion but can be distinguished from iliopsoas pathology by its more lateral location and well-defined origin at the AIIS.

Hip-related Pain

Articular hip pathology can cause groin pain and may be accompanied by mechanical symptoms or impaired joint motion.⁷ Femoroacetabular impingement (FAI) is defined as impingement of the acetabular labrum and femoral articular cartilage due to bony acetabular over-coverage, loss of femoral head sphericity, or both. It can be a common source of groin pain in athletes, resulting in secondary abnormal biomechanics about the hip joint.^{15,20,21} The radiographic presence of FAI morphology with positive physical exam findings of symptomatic FAI (pain with flexion/adduction/internal rotation at the hip) should warrant evaluation for other etiologies of groin pain listed in Table 1 (see Page 2).

Neuropathic Pain

Several peripheral nerves can become compressed or entrapped along their course to the groin and cause pain, paresthesias, dysaesthesia, or numbness. The nerves include the genital and femoral branches of the genitofemoral nerve, the obturator nerve, or the medial femoral cutaneous nerve.¹⁰ Figure 2 illustrates the skin locations commonly innervated by

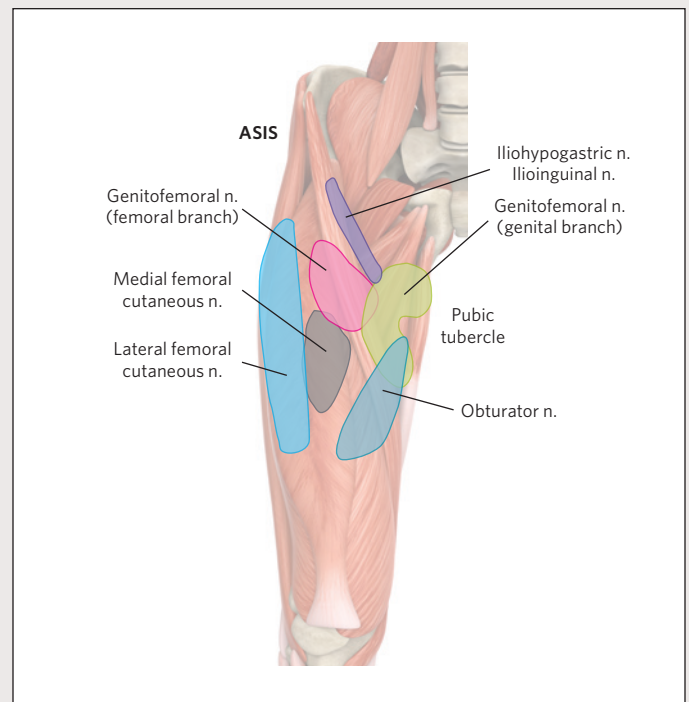


Figure 2. Common cutaneous innervation of nerves in the thigh and groin. ASIS – Anterior Superior Iliac Spine.

peripheral nerves in the groin and demonstrates that nerve territories will frequently overlap. Neuromuscular weakness is not a common finding, as most peripheral nerves to the groin are pure sensory nerves that do not carry motor fibers.

Imaging

Plain radiographs of the pelvis, hip joints, and pubic symphysis can identify fractures, neoplasms, avascular necrosis, FAI morphology, and symphysis degenerative disease.⁷

MRI can identify pathological edema, which can be present with stress fractures, as well as deep fascial, musculotendinous, and bony anatomy. The MRI protocol should include large field-of-view sequences for the bony pelvis and hip joint with focused smaller field-of-view sequences to evaluate the pubic symphysis.¹⁶ As always, clinical examination with correlation to imaging findings is critical as MRI abnormalities are not

Osteitis Pubis	<p><i>Acute:</i> Bone marrow edema involving subchondral bone at pubic symphysis extending from anterior to posterior. Edema is typically bilateral but asymmetric with the symptomatic side demonstrating more advanced edema.</p> <p><i>Chronic:</i> Osteophytes, sclerosis, and subchondral cysts are often present.</p>
Midline Rectus Abdominis/ Adductor Aponeurotic Plate Injury	<p>Hyperintensity on T2 images extending bilaterally from midline pubic symphysis to form the appearance of a bilateral secondary cleft.</p> <p>Visible extension of injury into one adductor longus tendon indicates interstitial tearing.</p> <p>Osteitis pubis is common in the setting of pubic plate lesions.</p>
Adductor Injury	Hyperintensity on T2 involving the myotendinous junction. Injuries are graded similarly to other muscle strains throughout the body.
Rectus Abdominis Strain	Increased intramuscular signal with feathery edema. Uncommon injury pattern.
Accessory Flexor Lesions	Myotendinous edema, avulsion, peritendinous edema or tendinous enlargement or nodularity of hip flexor tendons.
Iliopsoas Bursitis	T2 hyperintense fluid between the anterior hip capsule and distal iliopsoas tendon, lateral to the femoral neurovascular bundle.
Hip Disorders	Anterosuperior acetabular labral tears may be present. Secondary signs of labral pathology include paralabral cysts and joint effusion.

Table 2: MRI findings in pathologies commonly related to groin pain in athletes.

always symptomatic. This finding was illustrated in a study of NFL Scouting Combine participants that showed no differences in Scouting Combine performance in asymptomatic athletes with and without musculoskeletal groin abnormalities on MRI evaluation.^{7,22,23}

The most common MRI findings in athletes with long-standing groin pain are degenerative changes of the pubic symphyseal joint, adductor myotendinous insertional pathology, pubic bone marrow edema, and secondary cleft signs.⁵ Table 2 outlines MRI findings in pathologies commonly related to groin pain in athletes.¹⁶

Ultrasound (US) can provide a focused and dynamic assessment of abnormalities around the groin, usually in greater anatomic detail than MRI when performed by a skilled and experienced sonographer.²⁴ This facilitates more precise localization of tears to the apophysis, tendon, myotendinous junction, or to the muscle, which can inform return-to-play and discussion of procedural or operative interventions. Sonopalpation also can localize and confirm symptomatic pathology.

^{99m}Tc MDP bone scan can assist in diagnosis of stress fractures, osteomyelitis, synovitis, sacroiliitis, and tenoperiosteal lesions.¹⁹ Computed tomography (CT) has utility in the diagnosis of apophysitis, a source of groin pain in adolescents, but risks of ionizing radiation exposure often outweigh the benefits in younger populations.⁷

Management

Nonoperative Management

A 2015 systematic review and meta-analysis demonstrated similar return-to-play times between surgical and rehabilitative interventions, although with a low quality of evidence.²⁵ As a result, nonsurgical management typically is recommended as a first-line treatment.⁷ Initial treatment of groin injuries involves rest, ice, analgesics, and oral anti-inflammatory medications.^{19,26} Sports medicine physicians widely promote the use of NSAIDs in the first two to three days after injury for muscular and tendinous injuries, but no specific recommendations exist for groin pain. Current evidence suggests that NSAIDs are effective for treatment of tenosynovitis and soft tissue impingement, but they are not recommended for chronic isolated tendinopathy.^{27,28}

A physical therapy prescription from the physiatrist should initially include isometric exercises of hip flexors, extensors, abductors, and adductors in addition to abdominal musculature, with an emphasis on transversus abdominis and internal

obliques as tolerated with pain.¹⁹ As many as 60 to 80 percent of patients respond to such initial management.^{29,30} Therapies should progress to isokinetic strengthening, healthy functional movement patterns, and, ultimately, sport-specific training.^{1,19,26} Resisted sit-ups have some clinical utility for pubic pathologies but are not specific and may exacerbate other pathologies, such as posterior abdominal wall defects.⁷

Multimodal treatments are often prescribed, including manual adductor manipulation (passive stretching of the adductor muscles after prewarming), deep heat, therapeutic ultrasound, and iontophoresis. These modalities can facilitate earlier return-to-play than supervised training alone but have less long-term success in addressing symptoms when performed in isolation.^{5,13} For athletes with adductor-related groin pain, supervised physical training results in a high percentage of return-to-play when compared to passive PT modalities.^{5,29}

Pubic symphysis edema without fracture is a self-limited disease but has an average recovery of nine to 10 months.¹¹ Athletes should maintain a moderate level of low-impact aerobic activity as able while being careful to avoid provoking pain.¹¹ Therapy to increase range-of-motion and soft tissue flexibility at the hip may improve motion through the sacroiliac joint and reduce compensatory excessive motion at the pubic symphysis.¹¹

Interventions

Corticosteroid injections for the treatment of groin pain and core muscle injuries in the athlete are commonly performed, but large outcome studies are lacking.^{26,31} Image-guided injection of corticosteroid and local anesthetic injections into specific tendinous, fascial, or articular targets can be attempted to confirm the diagnosis.³² Limited retrospective evaluations suggest therapeutic corticosteroid injections may have only short-term positive effect^{33,34} and are best utilized to facilitate participation in PT and improve movement patterns.

Percutaneous needle tenotomy for chronic tendinosis and partial tendon tearing has been recognized to induce a controlled acute injury with associated bleeding which recruits platelets and additional growth factors and cytokine-releasing cells to the chronically injured tissue.³⁵ Pairing such procedures with PT can successfully improve symptoms and tendon fiber alignment.³² Platelet-rich plasma (PRP) also has been used in conjunction with percutaneous needle tenotomy to enhance the healing response via release of growth factors from platelets.³²

However, the use of PRP for treatment of adductor and rectus abdominis-adductor aponeurosis plate injuries in athletes should be used with caution as heterotopic ossification foci have been reported.²⁶

Surgery

The decision for surgical treatment should comprise a multidisciplinary discussion among sports medicine physicians, radiologists, athletic trainers, physical therapists, and surgeons when nonsurgical treatment fails.^{19,26,36} The goal of surgery is to restore normal anatomy and biomechanics across the pubic bone.^{1,19} Overall, surgical intervention for groin pain in the athlete has a low rate of complication (10 percent) and can be very successful in alleviating pain (90 percent) and returning athletes to play when paired with high-quality preoperative and postoperative rehabilitative care. Multiple surgical techniques exist but have not been compared directly to discern superiority.¹⁹

Laparoscopic hernia surgery that involves suture plication of the inguinal canal posterior wall and decompression of the genital branch of the genitofemoral nerve is best for inguinal-related groin pain.³⁶ This can facilitate return-to-training at three or four days and full athletic activity by day five.³⁶ Overall, successful return is 80 to 100 percent.^{23,37,38}

Adductor tenotomy and partial adductor longus release have also been used to address refractory cases of adductor-related groin pain, but with less success than other interventions. In published studies, only 60 percent of athletes return to play at three to four months after this surgery.^{19,39,40}

When a fascial defect or weakness is identified, reinforcement with the insertion of mesh is often recommended.¹³ One randomized controlled trial demonstrated three-month return-to-play rates of 90 percent following endoscopic surgical mesh repair of inguinal canal posterior wall deficiency compared to 27 percent after nonsurgical treatment.³⁸ However, the insertion of mesh may result in restricted abdominal muscle motion secondary to localized adhesions with subsequent pathologic muscular stiffening.^{26,36}

Clinical Vignette Outcome

AD underwent diagnostic imaging. Pelvic radiographs showed that the pubic symphysis and hip joint had normal morphology without degenerative disease. Diagnostic sports ultrasound identified adductor longus tendinosis, an edematous adductor-rectus aponeurotic plate, and partial tearing to the rectus abdominis tendon at the pubic symphysis. MRI showed increased T2 signal within the adductor longus myotendinous junction and rectus abdominis, as well as T2 signal and clefting of the rectus abdominis-adductor aponeurotic insertion, suggesting detachment.

High-quality physical therapy was initiated, however symptoms persisted and precluded return to practice. An ultrasound-guided injection of platelet-rich plasma was injected to the right adductor longus, rectus abdominis, and aponeurotic plate. AD ambulated on axillary crutches for two weeks before resuming physical therapy. He could return to play with 75 percent improvement at six weeks following the PRP injection but was bothered by lingering pain. He consulted with a general surgeon because symptoms persisted after the PRP injections. AD decided to have laparoscopic surgery with repair of the adductor-rectus aponeurotic plate and rectus abdominis with partial adductor tenotomy. Physical therapy was initiated again after surgery. He did very well and returned to play at the start of the next rugby season without limitations or symptom recurrence.

References

- Omar IM, Zoga AC, Kavanagh EC, Koulouris G, Bergin D, Gopez AG, et al. Athletic Pubalgia and "Sports Hernia": Optimal MR Imaging Technique and Findings. *Radiographics*. 2008 Sep-Oct; 28(5): 1415-1438.
- Brooks JH, Fuller CW, Kemp SP, Reddin DB. Epidemiology of Injuries in English Professional Rugby Union: Part 2 Training Injuries. *Br J Sports Med*. 2005 Oct; 39(10): 767-775.
- Brooks JH, Fuller CW, Kemp SP, Reddin DB. Epidemiology of Injuries in English Professional Rugby Union: Part 1 Match Injuries. *Br J Sports Med*. 2005 Oct; 39(10): 757-766.
- Meyers WC, McKechnie A, Philippon MJ, Horner MA, Zoga AC, Devon ON. Experience With "Sports Hernia" Spanning Two Decades. *Ann Surg*. 2008 Oct; 248(4): 656-665.
- Weir A, Brukner P, Delahunt E, Ekstrand J, Griffin D, Khan KM, et al. Doha Agreement Meeting on Terminology and Definitions in Groin Pain in Athletes. *Br J Sports Med*. 2015 Jun; 49(12): 768-774.
- Whittaker JL, Small C, Maffey L, Emery CA. Risk Factors for Groin Injury in Sport: An Updated Systematic Review. *Br J Sports Med*. 2015 Jun; 49(12): 803-809.
- Thorborg K, Reiman MP, Weir A, Kemp JL, Serner A, Mosler AB, et al. Clinical Examination, Diagnostic Imaging, and Testing of Athletes With Groin Pain: An Evidence-Based Approach to Effective Management. *J Orthop Sports Phys Ther*. 2018 Apr; 48(4): 239-249.
- Meyers WC. Editorial Commentary: Core Muscle Injuries or Athletic Pubalgia—Finally the Real Sausage, Not Just the Same Ole Baloney. *Arthroscopy*. 2017 May; 33(5): 1050-1052.
- Weir A, Holmich P, Schache AG, Delahunt E, de Vos RJ. Terminology and Definitions on Groin Pain in Athletes: Building Agreement Using a Short Delphi Method. *Br J Sports Med*. 2015 Jun; 49(12): 825-827.
- Falvey EC, Franklyn-Miller A, McCrory PR. The Groin Triangle: A Patho-anatomical Approach to the Diagnosis of Chronic Groin Pain in Athletes. *Br J Sports Med*. 2009 Mar; 43(3): 213-220.
- Fricker PA. Management of Groin Pain in Athletes. *Br J Sports Med*. 1997 Jun; 31(2): 97-101.
- Serner A, Weir A, Tol JL, Thorborg K, Roemer F, Guermazi A, et al. Can Standardised Clinical Examination of Athletes With Acute Groin Injuries Predict the Presence and Location of MRI Findings? *Br J Sports Med*. 2016 Dec; 50(24): 1541-1547.
- Joesting DR. Diagnosis and Treatment of Sportsman's Hernia. *Curr Sports Med Rep*. 2002 Apr; 1(2): 121-4.
- Garvey JF, Hazard H. Sports Hernia or Groin Disruption Injury? Chronic Athletic Groin Pain: A Retrospective Study of 100 Patients With Long-term Follow-up. *Hernia*. 2014; 18(6): 815-823.

15. Naal FD, Dalla Riva F, Wuerz TH, Dubs B, Leunig M. Sonographic Prevalence of Groin Hernias and Adductor Tendinopathy in Patients With Femoroacetabular Impingement. *Am J Sports Med.* 2015 Sep; 43(9): 2146-2151.
16. Palisch A, Zoga AC, Meyers WC. Imaging of Athletic Pubalgia and Core Muscle Injuries: Clinical and Therapeutic Correlations. *Clin Sports Med.* 2013 Jul; 32(3): 427-47.
17. Santilli OL, Nardelli N, Santilli HA, Tripoloni DE. Sports Hernias: Experience in a Sports Medicine Center. *Hernia.* 2016 Feb; 20(1): 77-84.
18. Campanelli G. Pubic Inguinal Pain Syndrome: The So-called Sports Hernia. *Hernia.* 2010 Feb; 14(1): 1-4.
19. Sheen AJ, Stephenson BM, Lloyd DM, Robinson P, Fevre D, Paajanen H, et al. 'Treatment of the Sportsman's Groin': British Hernia Society's 2014 Position Statement Based on the Manchester Consensus Conference. *Br J Sports Med.* 2014 Jul; 48(14): 1079-1087.
20. Hammoud S, Bedi A, Magennis E, Meyers WC, Kelly BT. High Incidence of Athletic Pubalgia Symptoms in Professional Athletes With Symptomatic Femoroacetabular Impingement. *Arthroscopy.* 2012 Oct; 28(10): 1388-1395.
21. Hammoud S, Bedi A, Voos JE, Mauro CS, Kelly BT. The Recognition and Evaluation of Patterns of Compensatory Injury in Patients With Mechanical Hip Pain. *Sports Health.* 2014 Mar; 6(2): 108-118.
22. Branci S, Thorborg K, Nielsen MB, Holmich P. Radiological Findings in Symphyseal and Adductor-related Groin Pain in Athletes: A Critical Review of the Literature. *Br J Sports Med.* 2013 Jul; 47(10): 611-619.
23. Knapik DM, Gebhart JJ, Nho SJ, Tanenbaum JE, Voos JE, Salata MJ. Prevalence of Surgical Repair for Athletic Pubalgia and Impact on Performance in Football Athletes Participating in the National Football League Combine. *Arthroscopy.* 2017 May; 33(5): 1044-1049.
24. Brandon CJ, Jacobson JA, Fessell D, Dong Q, Morag Y, Girish G, et al. Groin Pain Beyond the Hip: How Anatomy Predisposes to Injury as Visualized by Musculoskeletal Ultrasound and MRI. *AJR Am J Roentgenol.* 2011 Nov; 197(5): 1190-1197.
25. King E, Ward J, Small L, Falvey E, Franklyn-Miller A. Athletic Groin Pain: A Systematic Review and Meta-analysis of Surgical Versus Physical Therapy Rehabilitation Outcomes. *Br J Sports Med.* 2015 Nov; 49(22): 1447-1451.
26. Poor AE RJ, Zoga AC, Meyers WC. Core Muscle Injuries in Athletes. *Curr Sports Med Rep.* 2018; 17(2): 54-58.
27. Paoloni JA, Milne C, Orchard J, Hamilton B. Non-steroidal Anti-inflammatory Drugs in Sports Medicine: Guidelines for Practical But Sensible Use. *Br J Sports Med.* 2009 Oct; 43(11): 863-865.
28. Hotfiel T, Seil R, Bily W, Bloch W, Gokeler A, Kriffter RM, et al. Nonoperative Treatment of Muscle Injuries - Recommendations From the GOTS Expert Meeting. *J Exp Orthop.* 2018 Jun 22; 5(1): 24.
29. Holmich P, Uhrskou P, Ulnits L, Kanstrup IL, Nielsen MB, Bjerg AM, et al. Effectiveness of Active Physical Training as Treatment for Long-standing Adductor-related Groin Pain in Athletes: Randomised Trial. *Lancet.* 1999 Feb 6; 353(9151): 439-443.
30. Weir A, Jansen JA, van de Port IG, Van de Sande HB, Tol JL, Backx FJ. Manual or Exercise Therapy for Long-standing Adductor-related Groin Pain: A Randomised Controlled Clinical Trial. *Man Ther.* 2011 Apr; 16(2): 148-154.
31. Campbell R. Ultrasound of the Athletic Groin. *Semin Musculoskelet Radiol.* 2013 Feb; 17(1): 34-42.
32. McCarthy E, Hegazi TM, Zoga AC, Morrison WB, Meyers WC, Poor AE, et al. Ultrasound-guided Interventions for Core and Hip Injuries in Athletes. *Radiol Clin North Am.* 2016 Sep; 54(5): 875-892.
33. Byrne CA, Bowden DJ, Alkhatat A, Kavanagh EC, Eustace SJ. Sports-Related Groin Pain Secondary to Symphysis Pubis Disorders: Correlation Between MRI Findings and Outcome After Fluoroscopy-Guided Injection of Steroid and Local Anesthetic. *AJR Am J Roentgenol.* 2017 Aug; 209(2): 380-388.
34. Jose J BL, Fokin A, Wodicka R, Subhawong T, Bryson L. Ultrasound-guided Corticosteroid Injection for the Treatment of Athletic Pubalgia: A Series of 12 Cases. *J Med Ultrasound.* 2015; 23(2): 71-75.
35. Housner JA, Jacobson JA, Misko R. Sonographically Guided Percutaneous Needle Tenotomy for the Treatment of Chronic Tendinosis. *J Ultrasound Med.* 2009 Sep; 28(9): 1187-1192.
36. Muschaweck U, Berger L. Minimal Repair Technique of Sportsmen's Groin: An Innovative Open-suture Repair to Treat Chronic Inguinal Pain. *Hernia.* 2010 Feb; 14(1): 27-33.
37. Jakoi A, O'Neill C, Damsgaard C, Fehring K, Tom J. Sports Hernia in National Hockey League Players: Does Surgery Affect Performance? *Am J Sports Med.* 2013 Jan; 41(1): 107-110.
38. Paajanen H, Brinck T, Hermunen H, Airo I. Laparoscopic Surgery for Chronic Groin Pain in Athletes Is More Effective Than Nonoperative Treatment: A Randomized Clinical Trial With Magnetic Resonance Imaging of 60 Patients With Sportsman's Hernia (Athletic Pubalgia). *Surgery.* 2011 Jul; 150(1): 99-107.
39. Schilders E, Dimitrakopoulou A, Cooke M, Bismil Q, Cooke C. Effectiveness of a Selective Partial Adductor Release for Chronic Adductor-related Groin Pain in Professional Athletes. *Am J Sports Med.* 2013 Mar; 41(3): 603-607.
40. Akermark C, Johansson C. Tenotomy of the Adductor Longus Tendon in the Treatment of Chronic Groin Pain in Athletes. *Am J Sports Med.* 1992 Nov-Dec; 20(6): 640-643.

UPMCPhysicianResources.com/Rehab



ADDRESS CORRESPONDENCE TO:

Michael C. Munin, MD

Senior Editor and Vice Chairman
Strategic Planning and Program Development
Department of Physical Medicine and Rehabilitation

Kaufmann Medical Bldg. T: 412-648-6848
Suite 201 F: 412-692-4410
3471 Fifth Ave. Email: muninmc@upmc.edu
Pittsburgh, PA 15213

A \$19 billion world-renowned health care provider and insurer, Pittsburgh-based UPMC is inventing new models of patient-centered, cost-effective, accountable care. UPMC provides more than \$900 million a year in benefits to its communities, including more care to the region's most vulnerable citizens than any other health care institution. The largest nongovernmental employer in Pennsylvania, UPMC integrates 85,000 employees, 40 hospitals, 600 doctors' offices and outpatient sites, and a 3.4 million-member Insurance Services Division, the largest medical insurer in western Pennsylvania. As UPMC works in close collaboration with the University of Pittsburgh Schools of the Health Sciences, *U.S. News & World Report* consistently ranks UPMC Presbyterian Shadyside on its annual Honor Roll of America's Best Hospitals. UPMC Enterprises functions as the innovation and commercialization arm of UPMC, and UPMC International provides hands-on health care and management services with partners around the world. For more information, go to UPMC.com.

ABOUT THE DEPARTMENT OF PHYSICAL MEDICINE AND REHABILITATION

- UPMC Presbyterian Shadyside is ranked by *U.S. News & World Report* as one of the nation's best hospitals for rehabilitation.
- The Department of Physical Medicine and Rehabilitation is consistently a top recipient of NIH funding for rehabilitation-related research.
- The Spinal Cord Injury Program at UPMC is one of only 14 in the country selected by the National Institute on Disability, Independent Living, and Rehabilitation Research (NIDILRR) as a model for other rehab providers.
- Department clinicians lead UPMC's rehabilitation network of more than 90 inpatient, outpatient, and long-term care facilities — one of the country's largest.