

Accreditation Statement

The University of Pittsburgh School of Medicine is accredited by the Accreditation Council for Continuing Medical Education (ACCME) to provide continuing medical education for physicians.

The University of Pittsburgh School of Medicine designates this enduring material for a maximum of 0.5 AMA PRA Category 1 Credits™. Each physician should only claim credit commensurate with the extent of their participation in the activity. Other health care professionals are awarded 0.05 continuing education units (CEU), which are equivalent to 0.5 contact hours.

Disclosures

L. Dade Lunsford, MD, is a consultant for DSMB and Insightec. He is also a stockholder in Elekta AB. Nduka Amankolor, MD, is a consultant for Oncorus, Inc.

Instructions

To take the CME evaluation and receive credit, please visit UPMCPPhysicianResources.com/Neurosurgery and click on the course *Neurosurgery News* September 2017.

New Hope for Life After Hemorrhagic Stroke

by Brian Jankowitz, MD

Hemorrhagic stroke, while much less common than ischemic stroke, makes up 10-20% of all strokes. Despite its lower incident rate, it still has a deadly and debilitating nature — a mortality rate of 35-52% with 80-90% of patients left with significantly disabled speech, motor skills, and cognitive function.

For the 100,000 people who suffer an intracranial hemorrhage (ICH) each year, 95% receive standard medical management. That means more than 95,000 people who suffer an ICH this year will be medically managed in the intensive care unit using 50-year-old protocols that come with substantial medical costs, totaling nearly \$13 billion annually for patient care, recovery, and rehabilitation.

Interest in the surgical management of ICH has waned over the last decade due to the lack of evidence. Prior studies such as STICH and STICH 2 randomized patients to medical management or surgical evacuation of supratentorial hemorrhages. Neither study showed a significant benefit to surgery. This caused a deep sense of nihilism in the surgical community, leaving even more patients subject to a standard of care that had not changed in decades. The studies were well-conducted, but failed to show a benefit for a variety of reasons, including an inadequate length of follow-up, the wrong outcome measures, the absence of new technology in this field, and the lack of a standardized surgical approach. The MISTIE trial addressed these concerns and, in the phase II trial, showed some exciting trends towards clinical improvement after surgical removal of the hematoma, as well as a statistically significant cost savings and decreased length of stay. The MISTIE III trial is currently ongoing and should be completed within the next year.

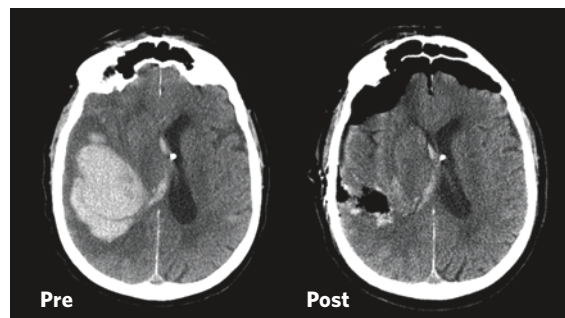


Figure 1: Non-contrast CT pre/post surgery showing a 95% hematoma removal with resolution of mass effect and midline shift.



Figure 2: The NICO Myriad device is designed to maximize hematoma removal while protecting normal brain.

The ENRICH trial (**E**arly **Mi**nimally-invasive **R**emoval of **ICH**) represents the next phase of trials designed by surgeons to further address the shortcomings of previous studies. This randomized, controlled trial will enroll up to 300 patients and compare standard medical management to early surgical hematoma evacuation (operating within 24 hours of the bleed) using a minimally invasive approach incorporating the NICO BrainPath™ and Myriad®. These devices are FDA-approved surgical tools that have been used in more than 1,500 stroke

(Continued on Page 8)

Free Online CME

To take the CME evaluation for this issue, visit our education website: UPMCPPhysicianResources.com/Neurosurgery.

Chairman's Message

Leading the Way in Minimally Invasive Management of Neurosurgical Diseases



What does minimally invasive management mean? What are the advantages? Is a minimally invasive approach always superior? These are key questions practitioners and patients alike need to address, understand, and consider as a new minimally invasive procedure is developed and selected for the management of a specific pathology.

In this issue of University of Pittsburgh *Neurosurgery News*, our UPMC clinical leaders describe a number of minimally invasive approaches for the management of intracerebral hemorrhage and expanded endonasal approaches for the management of chordomas and odontoid pathologies. Furthermore, clinical leadership in radiosurgery enables the department to use a number of leading delivery platforms. Radiosurgery is clearly a minimally invasive approach, with our faculty playing a leading role in developing and researching new and improved applications. As minimally invasive approaches are developed and applied to patients, the above-stated questions must be considered.

Minimally invasive must be an overall management philosophy involving the least amount of tissue disruption. This encompasses

everything from the skin to the target pathology, including traversing normal brain tissue. Minimalism should not compromise overall outcome. Advantages must include a number of parameters — both short- and long-term — including hospital stay, return to work (timing and likelihood), prognosis, and management/control of the disease process.

University of Pittsburgh neurosurgeons have led the way in developing and carefully recording outcomes of these minimally invasive approaches. Our faculty not only help patients, but also help train other clinicians who visit Pittsburgh from around the globe to learn these minimally invasive approaches. We are proud to be a comprehensive academic department with an ingrained mission to push the boundaries of neurosurgery. We look forward to continuing to shape the future of neurosurgical care.

Robert M. Friedlander, MD, MA

*Chairman and Walter E. Dandy Professor of Neurological Surgery
Co-Director, UPMC Neurological Institute*

Faculty

Chairman

Robert M. Friedlander, MD, MA

Professors

C. Edward Dixon, PhD
Peter C. Gerszten, MD, MPH
L. Dade Lunsford, MD
John J. Moossy, MD
Ajay Niranjani, MD, MBA
David O. Okonkwo, MD, PhD
Ian F. Pollack, MD
Mingui Sun, PhD

Associate Professors

Jeffrey Balzer, PhD
Donald J. Crammond, PhD
Johnathan Engh, MD
Juan C. Fernandez-Miranda, MD
Paul A. Gardner, MD
D. Kojo Hamilton, MD
Adam S. Kanter, MD, FAANS
R. Mark Richardson, MD, PhD
Raymond F. Sekula Jr., MD, MBA
Nilkantha Sen, PhD
Parthasarathy D. Thirumala, MD
Elizabeth C. Tyler-Kabara, MD, PhD

Assistant Professors

Sameer Agnihotri, PhD
Nduka Amankulor, MD
Diane L. Carlisle, PhD
Pat Conway, PhD
(Executive Administrator)
Avniel Ghuman, PhD
Paola Grandi, PhD
Stephanie Greene, MD
Bradley Gross, MD
Luke Henry, PhD
Brian Jankowitz, MD
Gary Kohanbash, PhD
Edward A. Monaco III, MD, PhD
Ava Puccio, PhD, RN
Mandeep Tamber, MD, PhD
Fang-Cheng (Frank) Yeh, MD, PhD

Clinical Professors

Matt El-Kadi, MD, PhD
Joseph C. Maroon, MD
Daniel A. Wecht, MD, MSc
David S. Zorub, MD

Clinical Associate Professor

Michael J. Rutigliano, MD, MBA

Clinical Assistant Professors

J. Brad Bellotte, MD
Daniel M. Bursick, MD
David L. Kaufmann, MD
Vincent J. Miele, MD
Monte B. Weinberger, MD

Research Associate Professor

Hideyuki Kano, MD, PhD

Research Assistant Professors

Yue-Fang Chang, PhD
Wendy Fellows-Mayle, PhD
Esther Jane, PhD
Wenyan Jia, PhD
Daniel Premkumar, PhD
Tanusree Sen, PhD

Clinical Instructors

Jeffrey W. Bost, PA-C
Erin E. Paschel, PA-C

Chief Residents

Gurpreet S. Gandhoke, MD
Philip Lee, MD, PhD
David Panczykowski, MD
Gregory Weiner, MD
Georgios Zenonos, MD

Contact Us

Department of Neurological Surgery

UPMC Presbyterian
Suite B-400
200 Lothrop St.
Pittsburgh, PA 15213
412-647-3685

Editor: Peter C. Gerszten, MD, MPH

Website: neurosurgery.pitt.edu

Email: neuroinfo@upmc.edu

 Like us on Facebook @ [facebook.com/pitt.neurosurgery](https://www.facebook.com/pitt.neurosurgery)

 Visit us on youtube @ [youtube.com/neuroPitt](https://www.youtube.com/neuroPitt)

Thirty Years of Brain Gamma Knife Radiosurgery at UPMC

by **Ajay Niranjn, MD, MBA, and L. Dade Lunsford, MD**

In August 2017, UPMC and the Center for Image-Guided Neurosurgery at UPMC Presbyterian celebrated the 30th anniversary of the installation of the first dedicated 201-source cobalt 60 Gamma Knife® in the United States. The field of stereotactic radiosurgery (SRS) was established by Swedish neurosurgical pioneer Lars Leksell in 1951 as a minimally invasive option to treat deep brain lesions not as easily accessible by more conventional neurosurgical techniques.

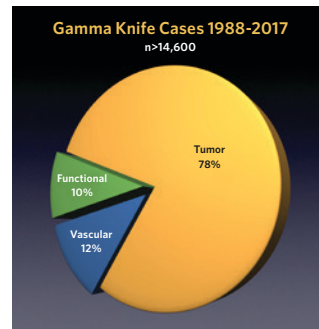
The first Gamma Knife (Model U) in North America was installed at UPMC in 1987. Since that time, the field has grown dramatically. The Center for Image-Guided Neurosurgery at the University of Pittsburgh continues to be a leader in this field. Over the three decades that surgeons at the University have worked with various models of Leksell's Gamma Knife, the technology has continued to improve.

Currently, two Gamma Knife units are in use at UPMC Presbyterian. Our center has the distinction of being one of few clinical sites in the world with two clinical units. In the fall of 2007, the Leksell Gamma Knife Perfexion™ was installed here. This Gamma Knife unit incorporates advanced robotics, expands the role of radiosurgery to include extracranial targets, provides greater patient access, and enhances patient safety.

In 2016, UPMC installed its sixth Gamma Knife, the newest generation Gamma knife Icon® with cone beam CT imaging. This latest model incorporates both frame-based and mask-based radiosurgery. Mask-based SRS expands the role of radiosurgery to include larger targets, which may benefit from fractionated dose delivery.

Gamma Knife technology represents one of the most advanced means available to help patients with brain tumors, arteriovenous malformations (AVMs), and pain or movement disorders. More than 14,600 patients have undergone Gamma Knife stereotactic radiosurgery at UPMC Presbyterian. Annually, our center

performs approximately 600-650 frame- or mask-based stereotactic radiosurgical procedures using the Gamma Knife. While in the beginning, treating vascular malformations of the

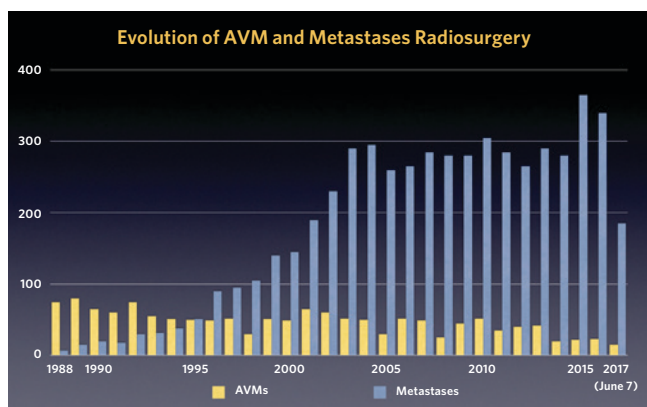


brain was the most common use of the device, the Gamma Knife is now most commonly used for metastatic and other tumors. Currently, 40% of these cases represent patients with solitary or multiple metastatic tumors. The application of SRS for the management of brain cancer has changed the paradigm of management for such

cases. Radiosurgery results in significantly less toxicity to the brain, can be repeated as needed in the development of new disease, does not impact the management of patients' ongoing chemotherapy for systemic disease and, finally, is associated with improved survivals and reduced costs in the management of intracranial disease.

Since 1987, our center has published more than 600 articles or book chapters on the role of Gamma Knife radiosurgery for many indications. The Center for Image-Guided Neurosurgery is also an international training site for radiosurgery, holding six, week-long training courses per year. These courses are among the highest-rated post-graduate courses offered at the University of Pittsburgh. More than 2,250 neurosurgeons, neurologists, radiation oncologists, medical physicists, and nurses have been trained at our center. In 2015, the center opened a new state-of-the-art education and training facility equipped with the latest generation high-definition display systems.

At UPMC Presbyterian, SRS represents a unique collaboration between health care professionals including neurosurgeons, radiation oncologists, medical physicists, and a dedicated nursing team. The Center for Image-Guided Neurosurgery, led by L. Dade Lunsford, MD, Lars Leksell Professor, incorporates the expertise of individuals in Gamma Knife radiosurgery, neuro-oncology, radiation oncology, neuro-radiology, and nursing. Ajay Niranjn, MD, MBA, is Associate Director of the Center. Edward Monaco III, MD, PhD, is co-Associate Director. This multidisciplinary center includes the clinical and research efforts of radiation oncologists John Flickinger, MD; Yoshio Arai, MD; and Susan Rakfal, MD. The participating medical physics group consists of Jong Oh Kim, PhD; Kevin Fallon, MS; and Greg Bednarz, PhD. We are grateful to our nursing and administrative staff for their dedication and commitment to providing the highest level of professional care to our patients.



Institutional Outcomes Research with Endoscopic Endonasal Approaches for Skull Base Chordoma

by Georgios A. Zenonos, MD, and Paul A. Gardner, MD

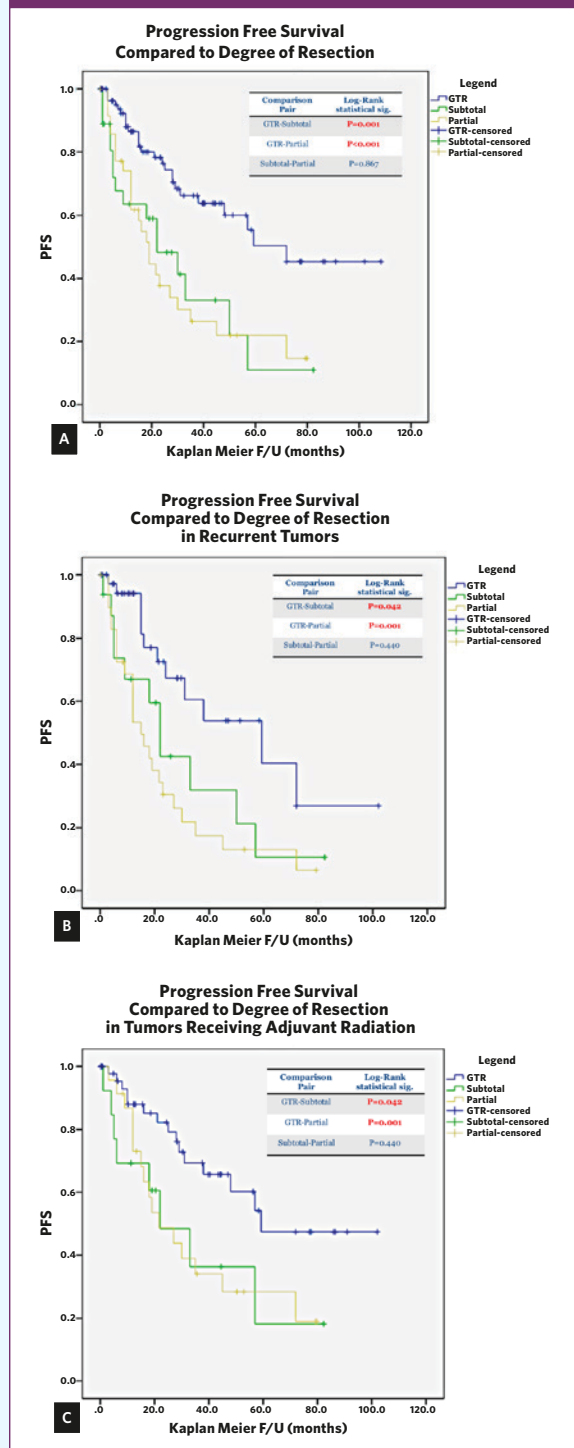
Skull base chordomas most commonly arise from the clivus and then extend laterally to involve other structures, often on either side of the midline. As such, they have been regarded as treacherous lesions to treat with traditional open/lateral approaches. The advent of endoscopic endonasal approaches (EEAs) has revolutionized the treatment of skull base chordomas, as the anterior surgical corridor provided by these procedures allows the surgeon to directly access the tumor to avoid working through the cranial nerves. In addition, these approaches have proven to be extremely versatile in the sagittal plane, providing access from the anterior cranial base all the way down to the craniocervical junction. As these approaches were pioneered at our institution, the University of Pittsburgh Center for Cranial Base Surgery has become a center referred worldwide for skull base chordomas. We recently reviewed our experience with EEAs for skull base chordomas over the past 12 years to understand the advances and limitations of this treatment.

After reviewing 151 EEAs for skull base chordomas, we found that our overall gross total resection rate (GTR) was 58%. However, we did find that we were much more effective in achieving total resection in primary tumors (GTR 73.4%) as opposed to recurrent ones (GTR 45.2%, $p=0.001$). Importantly, we also had a significant learning curve, with years of experience correlating strongly with our GTR, which now exceeds 70% overall. This correlation was even stronger for recurrent tumors ($P=0.003$). Nevertheless, we found involvement of the lower third of the clivus or the craniocervical junction, as well as significant lateral extension of the tumors, to be some of the limitations for total resections. Clinical improvement was the rule, with a much greater proportion of patients having reversal/improvement of their cranial neuropathies (40.3%) rather than deterioration (7.9%). Cerebrospinal fluid leaks remained the main complication of these approaches, occurring in up to 20% of patients.

A key observation was that total resection was the main determinant of progression-free survival for these tumors when compared to near-total, or partial, resections. This observation remained true when analyzing recurrent tumors and those that had received radiation (Table 1).

As a result, one of the main conclusions of the study was that every attempt should be made to achieve a total resection, even if this translates into multiple approaches. Given that the first attempt in resecting these tumors has the best chances of achieving a total resection, all these tumors are best treated at centers of excellence across the country. Improvement in our reconstructive strategies will be a main focus of future directions, and various in vitro models are currently being studied to advance this goal.

TABLE 1: Chordoma Clinical Outcomes



UPMC Trial of Neoadjuvant Radiosurgery Offers a Novel Treatment Option for Metastatic Brain Tumors

by **Johnathan A. Engh, MD**

Brain metastasis is a common and devastating complication of systemic cancer. It is estimated that 20-40% of patients with cancer will develop brain metastases, and this figure may be rising with improvements in available treatments and overall patient survival. Due to limited penetration of most chemotherapeutic agents across the blood-brain barrier, either radiation therapy and/or stereotactic radiosurgery (SRS) is generally required for successful control of intracranial metastatic disease. In general, we rely on radiation in its various forms to control metastatic disease to the brain.

For patients with limited systemic disease, high functional status, and larger lesions, surgical resection of a brain metastasis is the most effective method to achieve brain relaxation and alleviation of neurologic symptoms and signs. However, after metastasis removal, local recurrence rates approach 50% in the absence of adjuvant radiation therapy of some sort. Therefore, these patients generally will receive either adjuvant whole-brain irradiation or SRS to the resection cavity in order to maximize local control of disease and overall survival.

The trend toward local recurrence of surgically removed brain metastases in the absence of adjuvant radiation treatment creates a dilemma. SRS in general has a highly preferable side effect profile compared to whole brain irradiation. However, SRS requires substantial contouring and tumor targeting, which is far more difficult to achieve in the postoperative period, once tissue has been manipulated and a tumor has potentially been spilled. In addition, when adjuvant radiosurgery is performed after tumor removal, the highest dose generally goes to the center of the resection cavity, rather than the edges, where the radiation is most required. Finally, large brain metastases are especially prone to local failure when adjuvant SRS is used following surgical tumor resection.

An alternative management option for patients requiring resection of a brain metastasis is to perform radiosurgery in a neo-adjuvant fashion: i.e. to perform SRS prior to planned surgical resection. This strategy potentially obviates the difficulties of tumor contouring and local failure related to spillage of tumor cells around the resection cavity during surgery. At UPMC, a collaborative phase II clinical trial between the Departments of Radiation Oncology and Neurological Surgery is looking at local control rates and patient survivorship following neo-adjuvant SRS for selected brain metastases.

The trial targets patients with limited brain metastatic disease and one lesion that has been indicated for resection by the treating neurosurgeon. Reasons for the need to remove the lesion may include regional mass effect, symptomology, overall size, or

surrounding brain edema. Selected patients receive SRS first, then tumor resection within two to seven days of the neo-adjuvant treatment. Tumor samples are sent to the laboratory for analysis of early radiation treatment effects. The planned enrollment is 50 subjects, and the enrollment and treatment period has commenced with promising early results (Figure 1).

As survivorship of intracranial metastatic disease continues to increase, we will be challenged to provide better treatment options for brain disease in order to prevent neurologic morbidity and death. Our surgeons and radiation oncologists are hopeful that this trial will demonstrate an improvement over current treatment paradigms for our cancer patients.

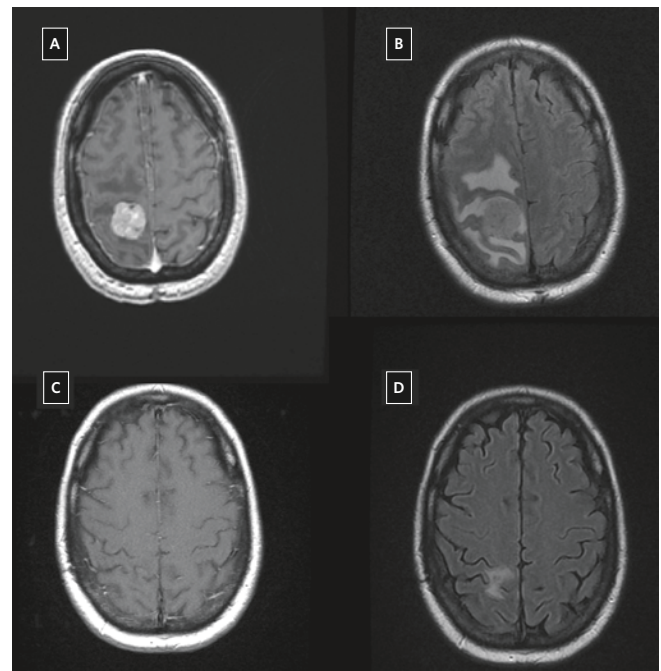


Figure 1: A 58-year-old man with renal cell carcinoma presents with left hemiparesis, headache, and steroid dependency. Panels **A** and **B** demonstrate a right parietal contrast-enhancing mass lesion with dramatic surrounding edema. The tumor was treated with Cyberknife stereotactic radiosurgery (18 Gray at 80% isodose line in a single fraction) followed by planned surgical resection two days post-treatment. Panels **C** and **D**, performed 3 months later, demonstrate complete resolution of contrast enhancement and near complete resolution of surrounding edema. The patient was easily weaned off steroids over the course of a week and had no neurological deficits at follow-up.

EEA for Odontoidectomy

by Nathan T. Zwagerman, MD, Juan C. Fernandez-Miranda, MD, and Paul A. Gardner, MD

The endoscopic endonasal approach (EEA) has been used successfully to access areas of the skull base from the anterior cranial fossa to the clivus. The natural extension of this approach involves lesions of the craniocervical junction and the odontoid. Traditional approaches to the odontoid involve the trans-oral route and have been used successfully in the past; however, three main problems have been observed: 1) long term palatal insufficiency is common, 2) oral flora pose a significant risk for wound infection and meningitis, and 3) enteral access and feeding are delayed. Using the EEA to reach the odontoid has been shown in a recent publication to significantly temper, if not remove, these issues postoperatively while successfully achieving the goals of surgery.

Our project evaluated the Pittsburgh experience from 2004 to 2013 using the EEA for odontoid decompression in 34 adults. The average age of the cohort was 71.5 years, with 59% being female. Most of these patients suffered from irreducible bony compression as a result of a calcified pannus (n=12) or basilar invagination (n=17) (Figure 1A). Almost all (n=31) of the patients had posterior fusions for stability in the postoperative setting. All patients had a radiographically confirmed decompression with either an intraoperative CT (Figure 1B) or X-ray with radio-opaque dye, and no patient required further decompression at the craniocervical junction. Neurologically, all patients either improved or stabilized. Decompression was further confirmed with follow up MRI/CT.

Postoperatively, no patient suffered from new, permanent palatal insufficiency. One patient suffered from an infection requiring debridement and antibiotics. In this series, 24 of the 34 patients were extubated by postoperative day 1 and were given a bedside swallow exam. The other 10 patients were kept intubated out of concern for aspiration (n=6) or for a planned posterior cervical surgery (n=4). Postoperative swallowing complications were directly related to preoperative dysphagia or cranial nerve palsies.

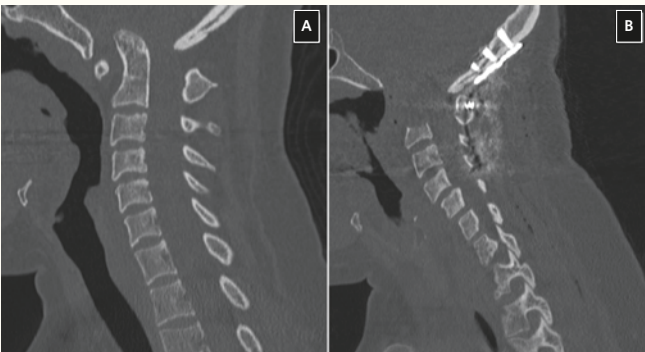

Figure 1: Non-contrast sagittal CT of the cervical spine. **A)** Preoperative scan indicating severe basilar invagination and canal compromise by the odontoid. **B)** Postoperative scan indicating complete resection of odontoid process and occipitocervical fusion.

Not surprisingly, of the six patients who had documented preoperative swallowing dysfunction, five had persistent difficulties after surgery and required a nasogastric feeding tube. Of the 18 patients who had no swallowing symptoms preoperatively, only two had significant swallowing problems after surgery, likely related to occipitocervical fusion. Other complications included one patient who suffered from severe epistaxis and was taken back into surgery for cauterization of the sphenopalatine artery, and two patients who had intraoperative cerebrospinal fluid (CSF) leaks, which were repaired with fat grafts and clips. No patient had a postoperative CSF leak.

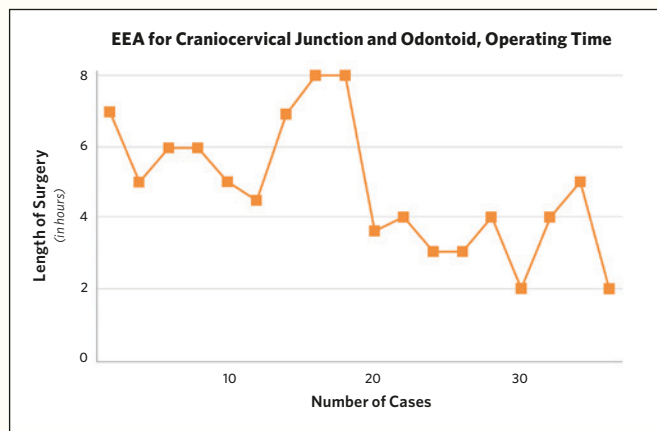


Figure 2: Graph demonstrating the improvement in operating times for the endoscopic endonasal approach (EEA) to the craniocervical junction and odontoid. Length of surgery includes intraoperative imaging such as CT.

The EEA to the odontoid is safe and effective for treatment of compressive pathology. However, patients still require posterior cervical fixation for stabilization, as their underlying pathology generally includes instability and the surgery disconnects the C1 anterior arch and removes the odontoid process. However, by first anteriorly decompressing patients who require ventral decompression, the posterior surgery may be performed without decompression, which allows a greater bony surface area for fusion and protection of the dura. This is especially important given the age of the patients involved and complex medical problems, including chronic steroid use in the setting of rheumatoid or other inflammatory arthritis. Of note, the surgical time for the EEA for odontoid resection has significantly decreased over the course of time. The initial surgeries took over five hours, but recent operative times have been three hours or less, indicating a significant learning curve associated with this surgery (Figure 2).

News & Notes

Pitt Neurosurgeons Named Best Doctors

Twenty University of Pittsburgh neurosurgeons were named among this area's leading doctors in their field in a national "Best Doctors" survey published locally in *Pittsburgh Magazine*.

The list includes: **Daniel M. Bursick, MD; Hikmat (Matt) El-Kadi, MD, PhD; Johnathan Engh, MD; Juan C. Fernandez-Miranda, MD; Robert M. Friedlander, MD; Paul A. Gardner, MD; Peter C. Gerszten, MD; D. Kojo Hamilton, MD; Brian Jankowitz, MD; Adam S. Kanter, MD; L. Dade Lunsford, MD; Joseph C. Maroon, MD; Edward A. Monaco III, MD, PhD; John J. Moossy, MD; Ajay Niranjana, MD; David O. Okonkwo, MD, PhD; Ian Pollack, MD; R. Mark Richardson, MD, PhD; Raymond Sekula, MD; and Elizabeth Tyler-Kabara, MD, PhD.**

An exhaustive peer review determines the physicians included in the list. Doctors cannot buy listings. Only those who earn the consensus support of their peers and meet additional qualification criteria are included.

Department Honors 2017 Chief Residents

A special black-tie graduation reception and dinner was held Saturday, June 17, at the Pittsburgh Golf Club honoring 2017 chief residents **Chris Deibert, MD; Zach Tempel, MD; and Nate Zwagerman, MD**, on their successful completion of the University of Pittsburgh's seven-year neurological surgery residency program. The event was attended by more than 100 faculty members, colleagues, family, and friends.

Upon graduation, Dr. Deibert is headed to Emory University in Atlanta; Dr. Tempel is going to Mayfield Brain & Spine in Cincinnati; while Dr. Zwagerman will be serving as an assistant professor at the Medical College of Wisconsin.

Department Hosts Course for Residents

From June 9-11, the Department of Neurological Surgery hosted the 2017 Stereotactic Radiosurgery Course for Neurosurgery and Radiation Oncology Residents, cosponsored by the American Association of Neurological Surgeons (AANS), the American Society for Radiation Oncology (ASTRO), and the Neurosurgical Education & Research Foundation (NERF).

The bi-annual course supports all expenses for senior neurosurgery and radiation oncology residents who have an interest in pursuing stereotactic radiosurgery as a subspecialty and are selected to participate by their program directors.

More than 20 distinguished neurosurgeons, radiation oncologists, and medical physicists served as faculty members. Participating department faculty included **Johnathan Engh, MD; Robert M. Friedlander, MD; Peter C. Gerszten, MD; L. Dade Lunsford, MD; Ajay Niranjana, MD; Edward A. Monaco III, MD, PhD; and Philip Lee, MD, PhD.** **John Suh, MD**, of the Cleveland Clinic and **Jason Sheehan, MD, PhD**, of the University of Virginia served as course directors.

More than 30 residents from across the country attended the course. Attendees were chosen in an equal distribution from the four geographical quadrants of the U.S. residency training programs.

Congratulations

Zach Tempel, MD, was selected as the best resident teacher by department faculty for 2016-17. **Juan C. Fernandez-Miranda, MD**, received the best faculty teaching award as selected by the residents.

The University of Pittsburgh resident team of **Ezequiel Goldschmidt, MD, PhD; William Ares, MD; Michael McDowell, MD; and Jeremy Stone, MD**, finished second nationally at the American Association of Neurological Surgeons Top Gun surgical competition held April 24-26 at the organization's annual scientific meeting in Los Angeles. Dr. McDowell won gold in the lumbar pedicle screw placement individual event.

Sameer Agnihotri, PhD, received the Marlene Reimer Brain Star of the Year award by the Canadian Institutes of Health Research in May.

Nitin Agarwal, MD, won the first place Socioeconomic E-poster Award at the 2017 American Association of Neurological Surgeons Scientific Meeting for his abstract, *An Assessment of Medical Malpractice Litigation in Neurosurgery*.

Shawn Walls, MEG Coordinator at the UPMC Brain Mapping Center, has become the first certified MEG (Magnetoencephalogram) technologist in the United States.

Raymond F. Sekula, MD, received the University of Pittsburgh's Allen Humphrey Excellence in Mentoring Award. Dr. Sekula was also nominated for the UPMC Center for Nursing Excellence's Champion of Nursing Award.

Special Lectures and Appearances

A surgical demonstration case for a complex pituitary tumor, performed by University of Pittsburgh Center for Cranial Base Surgery's **Juan C. Fernandez-Miranda, MD**, and **Eric Wang, MD**, at the National Skull Base Conference and Hands-on Anatomy Course at Tangdu Hospital in Xi'an, China, attracted more than 20,000 online viewers on April 12. The case, performed using the endoscopic endonasal approach pioneered by the neurosurgeons and ENTs at the Center for Cranial Base Surgery, was discussed extensively in the Chinese social medical network.

David O. Okonkwo, MD, PhD, was a visiting professor at Ajou University in Suwon, South Korea, on June 8.

Paul Gardner, MD, and **Carl Snyderman, MD, MBA**, served as special international guest faculty of the Beijing International Congress of Neuroendoscopy and Workshop held in Beijing from May 18-20. Following their cadaver session, live surgery and lectures, they were awarded guest professor appointments at the Beijing Neurosurgical Institute of Beijing Tiantan Hospital of the Capital Medical University and China-USA-Italy Endoscopic Neurosurgery Training Center.

In the News

R. Mark Richardson, MD, PhD, was featured in *Pittsburgh Magazine's* May 2017 "Best Doctors" issue in an article that discussed how 3D brain mapping technology helped changed the life of an epilepsy patient.

Brian Jankowitz, MD, was featured in a *Pittsburgh Post-Gazette* article on May 30 about the future of hemorrhagic stroke treatment. (See related article, Page 1.)

A patient of **D. Kojo Hamilton, MD**, was featured in a UPMC HealthBeat promotional video that described the successful treatment of degenerative disc disease pain through a specially designed, comprehensive physical therapy program. The video can be viewed at share.upmc.com/2017/05/paul-eugene-story.

New Hope for Life After Hemorrhagic Stroke *(Continued from Page 1)*

surgeries. The BrainPath involves a metal introducer that can be paired with any image guidance system. This introducer facilitates placement of a plastic, cylindrical sheath that is narrower than a dime. Once the sheath is docked in the hematoma, a multi-functional scissor and aspirating device called the Myriad (see Figure 2, Page 1) is inserted through the sheath to facilitate hematoma removal while protecting the adjacent, normal brain. Normal operative instruments such as a suction, bipolar, and bovie electrocautery can also be used through the port. The system enables a faster and more efficient removal of blood, with 95% of the hematoma consistently being removed.

The University of Pittsburgh is proud to be one of 13 sites that are currently enrolling in this trial. We are the only site in western Pennsylvania and have the fastest patient recruitment in the study to date. It is only by enrolling patients in trials such as these that we can push the field forward and give patients a shot at recovery that may not be possible otherwise.




Figure 3: The NICO BrainPath offers several different introducers and sheaths to accommodate any hematoma.

Free Online CME

To take the CME evaluation for this issue, visit our education website: UPMCPhysicianResources.com/Neurosurgery.

A \$14 billion world-renowned health care provider and insurer, Pittsburgh-based UPMC is inventing new models of patient-centered, cost-effective, accountable care. UPMC provides nearly \$900 million a year in benefits to its communities, including more care to the region's most vulnerable citizens than any other health care institution. The largest nongovernmental employer in Pennsylvania, UPMC integrates 65,000 employees, more than 25 hospitals, 600 doctors' offices and outpatient sites, and a 3.2 million-member Insurance Services Division, the largest medical and behavioral health services insurer in western Pennsylvania. Affiliated with the University of Pittsburgh Schools of the Health Sciences, UPMC is on the prestigious *U.S. News & World Report* annual Honor Roll of America's Best Hospitals. UPMC Enterprises functions as the innovation and commercialization arm of UPMC, while UPMC International provides hands-on health care and management services with partners in 12 countries on four continents. For more information, go to UPMC.com.

UPMC is proud to be the only hospital in western Pennsylvania to be named to *U.S. News & World Report's* prestigious national Honor Roll for excellence in 15 specialty areas, including neurology and neurosurgery. For more information about our programs, continuing medical education, Video Rounds, news, and events, please visit UPMCPhysicianResources.com/Neurosurgery.

